

XLVETS EQUINE - BETTER TOGETHER

Equine

MATTERS

www.xlvets.co.uk

Inside this issue:

COLIC FEARS

We explain the causes and treatment options illustrated by some real life case studies.


Foot care

Veterinary and farrier perspectives on foot lameness, balance and conformation



Practice Focus

In each issue of **Equine Matters** we feature a brief insight into a selection of the XLVets Equine Practices. Featured in this issue are Hook Norton, Clyde and Westmorland.



Banbury, Oxfordshire

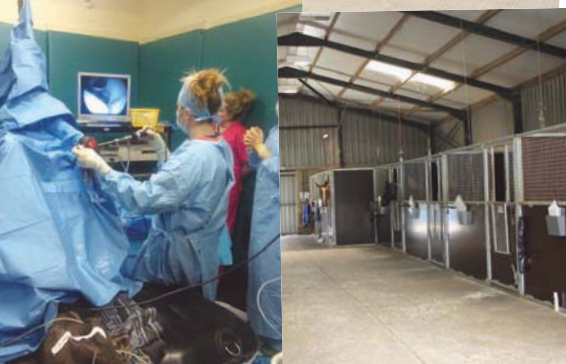Hook Norton Veterinary Group are a 15 vet practice near Banbury in North Oxfordshire, covering equine, farm and companion animals across Oxfordshire, Warwickshire, Gloucestershire and parts of Northamptonshire.

Our equine clients range from racehorses and eventers to family ponies and donkeys, for which we provide a 24-hour, 365-day service. The majority of our work is out and about at clients' premises, with the option to admit patients to our purpose-built clinic and surgical facilities for further investigation and treatment when appropriate. In-patients are looked after by our team of dedicated equine nursing staff.

We provide a wide range of services including vaccinations, dentistry, acupuncture, lameness investigations, shockwave treatment, pre-purchase examinations and exports. Our vets have access to mobile digital x-ray, ultrasound and ECG.

We aim to provide a high quality, value for money service, with case continuity whenever possible.

Find us on **facebook** or visit our website at www.hooknortonvets.co.uk

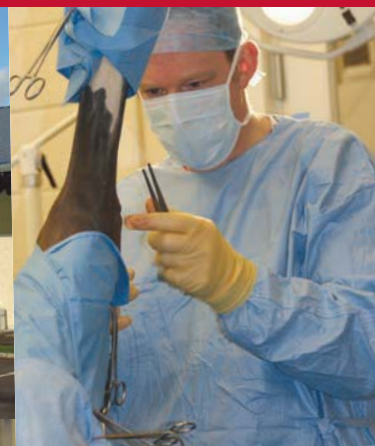

Lanark, Lanarkshire

Clyde Vet Group is a large practice serving central Scotland with a dedicated equine division. There are seven equine vets, including three certificate holders and a diploma holder, and four veterinary nurses/assistants. We provide high quality first opinion care and receive referrals from all over Scotland and the north of England. Clyde Vet Group Equine Hospital is the only privately owned RCVS Tier 3 Hospital in Scotland. The clinic has 11 stables, modern surgical facilities, a nuclear scintigraphy suite

and a full range of diagnostic equipment. We carry out lameness investigations, artificial insemination and medical work-ups. A specialist respiratory surgeon visits regularly to conduct surgical procedures. We aim to provide our clients with a first class service and our patients with excellent clinical care.

Visit our website at www.clydevetgroup.co.uk



Kirkby Lonsdale, Cumbria

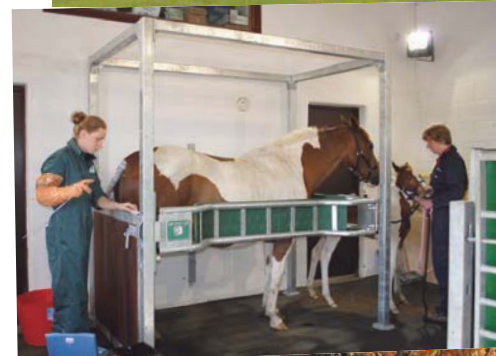Westmorland Equine is a team of four experienced, dedicated horse vets, covering the Lake District, Yorkshire Dales and Morecambe Bay. We are part of the larger Westmorland Veterinary Group, formed from the merger of two long established neighbouring mixed practices. We are RCVS Tier 2 accredited and a BEVA approved AI centre.

Mostly, we work on the road from our vehicles but our clinic at Kirkby Lonsdale has facilities for us to hospitalise sick or injured horses, perform minor surgeries and further investigate lameness cases.

We are well equipped to look after our patients, with all the things you would expect from an XLVets practice. We are strongly involved with the local equine community providing competition and racecourse cover as well as client meetings and support at local riding club events. We are privileged to enjoy good relationships with local farriers, EDTs and physiotherapists, enabling a holistic approach to horse health.

We pride ourselves on providing personal care and a professional service to all our clients ranging from much loved children's ponies to winners at Royal Ascot.

Visit our website at www.westmorland-vets.co.uk



SUMMER EDITION

XLVets is a novel and exciting initiative conceived from within the veterinary profession. We are all independently owned, progressive veterinary practices located throughout the United Kingdom committed to working together for the benefit of our clients.

XLVets Equine member practices

608 Farm & Equine Veterinary Surgeons

Alnthumbria Veterinary Group

Ardene House Veterinary Practice

Belmont Veterinary Centre

Bishopton Veterinary Group

Calweton Veterinary Group

Capontree Veterinary Centre

Castle Veterinary Surgeons

Chapelfield Veterinary Partnership

Cliffe Veterinary Group

Clyde Veterinary Group

Donald S McGregor & Partners

Drove Veterinary Hospital

Dunmuir Veterinary Group

Endell Veterinary Group

Fenwold Veterinary Centre

Glenthorne Veterinary Group

Hook Norton Veterinary Surgeons

Larkmead Veterinary Group

Midshire Veterinary Group Limited

Millcroft Veterinary Group

Minster Veterinary Practice

Northvet Veterinary Group

Paragon Veterinary Group

Parklands Veterinary Group

Penbode Equine Vets

Rosevean Veterinary Practice

Scarsdale Veterinary Hospital

Scott Mitchell Associates

St Boniface Veterinary Clinic

Wensum Valley Veterinary Surgeons

Westmorland Veterinary Group

Willows Veterinary Group

Wright & Morten

Equine Matters is published by:

XLVet UK Ltd, Carlisle House
Townhead Road, Dalston
Carlisle CA5 7JF

Tel: (01228) 711788

*This publication is supplied free of charge to equine clients of XLVets member practices.

© XLVet UK Ltd

No part of this publication may be reproduced without prior permission of the publisher.

Disclaimer:

XLVets does not necessarily share the views of contributors. No responsibility can be accepted for opinions expressed by contributors, or claims made by advertisers within this publication.

THE EDITOR

Welcome to the 'Summer 2013' edition of Equine Matters...

...produced by XLVets Equine practices.

This issue we focus on the foot; with articles from both the veterinary and the farrier perspective on foot lameness, balance and conformation. We also ask member vets their views on the old saying 'no foot no horse'.

One of the great fears of the horse owner is colic; inside we explain the causes and treatment options, illustrated by some real life case studies. Don't miss some great advice for improving the nutrition of both the performance horse and the rider and the second part of the peak performance series on eventing.

Enjoy the sunshine and long light evenings!

Liz Mitchell MA VetMB CertEP MRCVS
Scott Mitchell Associates



CONTENTS

- 03 **The causes and consequences of colic:**
Lee Pritchard, Calweton Veterinary Group explains what colic is and what it means if your horse has colic.
- 05 **Nursing feature: Nursing the colic case:**
Sarah Baillie, Ardene House Veterinary Practice focuses on the importance of nursing care in the colic patient.
- 07 **Case Report: Colic treated with medical management:**
Aimi Duff, Scott Mitchell Associates.
- 08 **Case Report: Colic requiring surgical treatment:**
Julian Rishworth, The Minster Veterinary Practice.
- 11 **MRI of the equine foot:**
Wendy Furness, Scarsdale Veterinary Group describes the advantages of MRI in the assessment of bones and cartilages within the foot.
- 12 **Foot balance explained:**
Chris Lehrbach, Chapelfield Veterinary Partnership explains how the horse's foot balance can be assessed.
- 13 **Trimming and shoeing for long-term soundness:**
Farrier Richard Chard discusses the important role of the farrier in identifying and correcting hoof distortions.
- 15 **Feeding for performance:**
Dr Teresa Hollands, Senior Nutritionist, Dodson & Horrell provides information on nutritional support and fitness for ourselves and our horses.
- 17 **Eventing: We ask the experts for tips on peak performance:**
David Rowlands, Penbode Equine Vets uncovers the common veterinary problems of the event horse and how they can be prevented.
- 19 **Foot conformation: what to look for:**
Richard Sutcliffe, Bishopton Veterinary Group focuses on how foot conformation relies upon a number of factors.
- 20 **Vet viewpoint:**
'Does the old saying 'no foot no horse' still apply today?'

SUMMER FEATURE

09

The foot as a cause of lameness:


Graham Hunter, Ardene House Veterinary Practice describes the method of investigation, management and treatment of foot lameness.





Lee Pritchard BVSc MRCVS Calweton Veterinary Group

The causes and consequences of colic...



Veterinary Surgeon **Lee Pritchard**

XLVets Equine Practice **Calweton Veterinary Group**



Colic is a term that strikes fear into many owners but what is colic and what does it mean if your horse has colic?



Well, all the term colic really describes is the behavioural signs associated with abdominal pain (of which there are a large number of causes). Broadly speaking when first assessing a horse with colic it is necessary to differentiate between those that are associated with the gastrointestinal tract and 'false colic' i.e. those conditions that present to us as colic but do not involve the gastrointestinal tract (such as laminitis, ovarian disease and bladder stones). For the purposes of this article we shall be focussing on causes of colic involving the gastrointestinal tract.

A horse that is colicking can do so for many reasons and so clinical signs can vary greatly. Different stages of colic can present in a number of ways and one horse will not always look the same way as another suffering from the same condition. Generally signs of colic in horses can include one or all of the following; pawing at the ground, flank watching, curling their lip or just not settling,

rolling, restlessness and lying down for prolonged periods and sweating up. Self trauma is often noted from damage sustained.

Pain in colic is generally a result of either stretching or distension of the intestines with gas/fluid/food; uncoordinated contraction or spasm of the intestines; loss of blood supply to a length of intestine or stretching of the mesentery (a fold of tissue that attaches organs to the body wall).

Types and causes of colic

Defining the type of colic involved enables the most appropriate treatment and prognosis to be established.

Causes of colic associated with the small intestine include pedunculated lipoma (a fatty lump that wraps itself around a piece of intestine strangulating it), ileal impaction, herniation, grass sickness, epiploic foramen entrapment (a piece of intestine becomes

trapped in a narrow opening within the abdomen) and enteritis (inflammation of the intestine).

Causes of colic associated with the large intestine include pelvic flexure impaction, displacement, tympany (over-production of gas), volvulus (360° rotation of the large intestine) and sand impaction.

Spasmodic colic is the most common colic encountered, is often mild and typically lasts a couple of hours. Loud gut sounds are often heard over large areas of the gastrointestinal tract and will respond well to gut relaxants and pain killers. High parasite burdens and sudden changes in diet are most frequently implicated.

Diagnosis of colic

A thorough history and clinical examination are the most useful diagnostic tests available to us. However to build up a full picture and likely prognosis we often use a number of adjunctive tools such as ultrasonography of the abdomen, passage of a stomach tube, removal and assessment of free fluid within the abdomen (abdominocentesis), blood sampling and in some cases exploratory surgery.



Assessing gut sounds



A horse pawing the ground. A common sign of colic.

Prevention of colic

Prevention is always better than cure and certainly some cases of colic are preventable. Regular dental examination allows identification of problems affecting chewing thus reducing the risk of certain types of colic. This is routinely performed every 6-12 months by a vet or qualified equine dental technician.

Regular monitoring and appropriate treatment of intestinal parasites will reduce the risk of colic (generally spasmodic colic, some impactions and damage caused by migration). Blanket treatment of all horses every 4-6 weeks is no longer an appropriate method of parasite control.

Worm egg counts from faecal samples provide us with information on worm burden and species of worms responsible. Tapeworms are not reliably measured from worm egg counts and so a separate blood sample is required for evaluation.

Horses are creatures of routine and as trickle feeders it is important that a regular feeding regime is maintained. Changes in both routine and diet can cause colic with any change in diet increasing the risk for up to 14 days after. With this in mind, keep to a strict routine (this involves not only the same timings everyday but it has been shown that the same person feeding everyday reduces risk) and any changes in feed must be introduced or removed slowly.

Some vices predispose a horse to colic, especially those that crib bite and windsuck. Horses that have had colic in the past are more likely to have colic in the future.

It is always advisable to investigate mild episodes of colic (a worm egg count, tapeworm blood test and a dental examination are good places to start) as these are often an indication of an underlying problem and by investigating early, later suffering can often be avoided.

Treatment of colic

When assessing a horse or pony with colic a decision needs to be made whether or not to treat medically or surgically. In some cases there is overwhelming evidence to support a diagnosis of a surgical condition, however there are numerous cases that require surgical intervention but do not always present to us as a severe colic. Therefore any horse with colic potentially has a life threatening condition and should be seen by a veterinary surgeon.

Approximately 90% of colic cases will respond to medical therapy including the use of gut relaxants, pain killers, lubricants, fluids and exercise. Gut relaxants are used in those horses that have evidence of gut spasm as the cause of pain and often provide good clinical results to treatment. Pain killers are an important part of colic treatment; there are a number available to us that all vary in their duration and effectiveness. Lubricants and fluids are used



to relieve impactions, most commonly passed via a tube into the stomach. Gentle exercise is used as a treatment for some conditions to relieve gas distension or to help to move parts of the large intestine to their proper position.

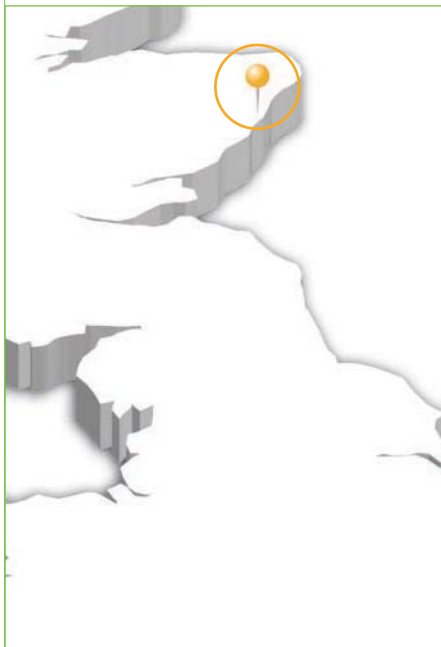
Surgical colic's make up approximately 10% of cases and it is not often that a definitive diagnosis is made until surgery is underway. The procedure performed depends on the cause of colic but surgery can involve removal of sections of dead intestine, returning sections of intestines to their normal anatomical position after displacement, relieving obstructions, relieving impactions or intestinal biopsies.

What do I do if my horse has colic?

Call the vet! Colic is potentially life threatening and so any horse showing colic signs should be seen by a veterinary surgeon.

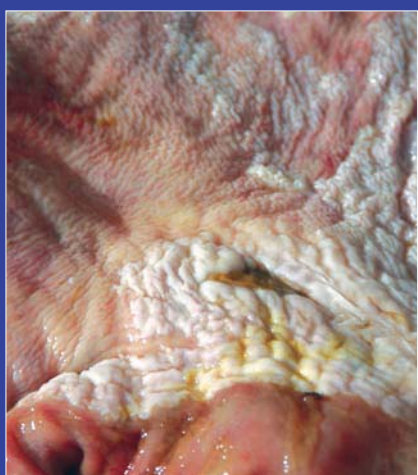Whilst you wait for the vet, walk your horse around to prevent any secondary injuries from rolling etc.

Think of your own safety first so do not enter the stable if your horse is violently colicking, wait for the vet.



Veterinary Nurse Sarah Baillie

XLVets Equine Practice Ardene House Vet Practice Ltd



Gastric ulcers can be a cause of colic

Sarah Baillie REVN MBVNA Ardene House Vet Practice Ltd

Nursing the colic case

Colic is abdominal pain or discomfort and is one of the most common medical conditions of the horse. For this reason it is sensible to think about what may be required should your horse suffer from colic. It can be distressing to see your horse in pain and fast decision making could be important in obtaining vital treatment.

Consider these questions:

- Can you easily contact your vet from your yard?
- Does everyone who cares for your horse know who to contact in an emergency?
- How would you transport your horse to a veterinary hospital at very short notice (possibly at night)?
- Is your horse insured and does the policy cover colic?
- Would you consider allowing your horse to undergo colic surgery?

If your horse has colic

Signs of colic include:

- pawing at the ground and box walking;
- looking round at (or sometimes biting at) the abdomen;
- rolling and getting up and down frequently
- sweating
- breathing fast
- restlessness and general discomfort

It is important to contact your vet if you believe your horse is suffering from colic and not administer any medications or home remedies as they may be contra-indicated. While waiting for the vet to arrive remove

any food and ensure the horse doesn't eat any bedding. Gentle walking can be helpful but only if it is safe to do so. It may be safest to walk the horse on a lunge line in a sand school to allow them to roll without hurting themselves or you. Never put yourself in a situation where you could be trapped by a violently rolling horse, in severe cases the horse is often unaware of its surroundings and can inadvertently injure someone.

Following assessment by your vet, the colic will most commonly be treated medically but severe cases may need to be moved to a surgical facility for surgical treatment or in some cases the decision may be made to euthanase the horse on humane grounds.

Hospitalisation for colic

Colic surgery is a major operation and several factors play a part in making the decision to undertake this procedure. Unfortunately cost often means surgery is not an option. It is an expensive procedure with long term intensive aftercare which means costs can easily add up. Having insurance does not necessarily mean the insurance company will cover the full bill. It's a good idea to check your policy to see if colic is excluded or if you have an injury only policy. Different policies have varying amounts of vets fee cover and so you may end up covering some of the cost yourself. It is important to remember that recovery from colic surgery is a long process and there are many potential complications which could prolong recovery further.

It's not only surgical colic cases which require hospitalisation; medical cases may require a stay in hospital too. It may be that frequency of checks and medication dictate the need for hospitalisation or it may be the type of treatment required. Any patient with colic will require regular observation. The vets and nurses will check vital parameters as well as listening to gut sounds, checking mucous membranes and capillary refill time.

Emphasis is placed on TLC for colic cases as being in an unfamiliar environment feeling unwell is obviously not pleasant. Regular grooming as well as walks outside (if not contra-indicated) can really help a patient's mental wellbeing. For patient's not receiving food or water by mouth, it is a good idea to periodically rinse the horse's mouth out to make it more comfortable.



Free access to water can help prevent colic

Home care following medical treatment

Specific home care instructions will depend on the condition treated but the main considerations are usually diet and exercise. Feeding small frequent amounts of fibre may be required as well as walking out to grass progressing to turnout. Feeds should be well wetted and hay soaked or steamed as well as free access to fresh clean water. Monitoring should include appetite, the amount of food eaten and dropping production.

Water intake should also be monitored and if insufficient amounts are being taken then the horse will need encouragement to drink. This can be done by flavouring the water with fruit juice, the addition of salt in feed or a salt lick. A clean deep bed is a good idea both for comfort and in case of recurrence of colic episodes. Bedding should not be edible, so shavings or paper would be preferable.

Home care following surgery

Once the horse is at a suitable point to be discharged aftercare will be continued at home. A long period of box rest, possibly one to two months, may be required as well as in-hand walking.

Careful monitoring of the surgical incision is important and any sign of wound breakdown, discharge, heat or swelling should be mentioned to your vet. Staples or stitches are usually removed around two weeks after surgery if there are no complications.

Your horse will have received post-operative antibiotics however a potential complication of abdominal surgery is peritonitis and endotoxaemia which can lead to laminitis. Monitoring for an increase in temperature

and heart rate and the presence of strong digital pulses can help detect these potential problems.

Feeding may involve a laxative diet of grass, hay and fibre with a feed balancer in small frequent amounts.

Faecal output should be closely monitored to ensure a sufficient amount is being passed. Consistency should also be noted as a change can indicate problems for example diarrhoea may be an indicator of colitis triggered by antibiotic administration. Remember when caring for your horse following colic surgery if you have any concerns contact your vet or nurse, there's no harm in being cautious.




Prevention

It's worth mentioning some measures which may help prevent some cases of colic. **These include:**

- making any changes in diet or management as gradually as possible;
- ensuring free access to water and feeding a moist diet;
- feeding plenty of fibre;
- regular worming and/or worm egg counts;
- having dental checks/teeth rasping every 6-12 months;
- preventing your horse from eating its bedding;
- avoiding grazing on sandy soil or if this is not possible feeding a psyllium husk supplement to aid passage of sand;
- if your horse is prescribed box rest ensure hay and feed is soaked and ensure adequate water intake;
- following sedation or anaesthesia follow your vet's feeding recommendations.



Scott
& Mitchell
Associates
VETERINARY
SURGEONS



Veterinary Surgeon Aimi Duff

XLVets Equine Practice Scott Mitchell Associates



Aimi Duff BVM&S MRCVS Scott Mitchell Associates

Colic treated with medical management

Ginger, a nine year old mare presented with colic pain. She had never been known to colic before, and had been wormed regularly.

Ginger was normally turned out full time, but in the preceding 48 hours she had been stabled to keep another horse company. She had been eating hay as normal but by the time of presentation was off food. No droppings had been passed in the last 12 hours.

Ginger was lying down and occasionally attempting to roll. Her membranes were moist and pink; indicating healthy circulation and good hydration. Ginger's heart and breathing rates were normal and her temperature was normal. Ginger had reduced gut sounds and movement. A rectal examination was performed after a small dose of intravenous sedation was given.

Rectal examination is a useful to aid to diagnosis, allowing the vet to carefully feel for abnormalities in the back part of the abdominal cavity. A rectal examination will only be carried out when it is safe and appropriate to do so, as there is the possibility of injury to vet and horse.

Ginger was found to have a large 'pelvic flexure impaction'. The pelvic flexure is a narrowing in the left colon which courses through 180° making it susceptible to obstruction with food material. With continued feeding, impactions can become larger, causing colonic wall stretching and pain.

A diagnosis of a pelvic flexure impaction was made and Ginger was treated with an intravenous injection of an anti-inflammatory drug for pain relief. A naso-gastric tube was passed into her stomach, via the nose, to administer several litres of an electrolyte solution as well as three litres of mineral oil (liquid paraffin). The electrolyte solution increases hydration levels which can then improve intestinal movement. The oil can, in some cases, act as a lubricant to ease the passage of the dry food material through the bowel.



Assessing Ginger's gut movements



Ginger

Advice was given to restrict feeding to treats only, for example, carrots/apples/mints with occasional walking out in hand for small amounts of grazing. Water was available constantly and not restricted.

Ginger was re-examined the following day. The signs of abdominal pain had not changed and rectal examination revealed the impaction to be slightly firmer on palpation.

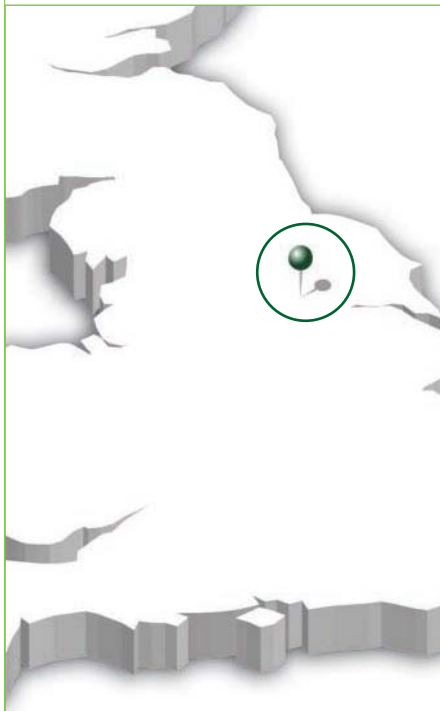
After discussion with her owner, Ginger was transported to the clinic for monitoring and further treatment. A nasogastric tube was passed to administer further large volumes of electrolyte solution. This was repeated every few hours throughout the day to over hydrate and soften the blockage, making it easier to pass. To keep Ginger comfortable, the oral fluid therapy was supplemented with low doses of intra-venous pain relief. The restricted diet and hand walking were continued to help stimulate intestinal movement whilst preventing the further build-up of food material in the gut.

24 hours after hospitalisation, Ginger was more comfortable and was passing soft droppings. Rectal examination confirmed the impaction had softened markedly and reduced in size. Ginger was monitored for a further 12 hours during which time, she was gradually weaned back onto her normal ration before being discharged.

It is likely Ginger's colic was associated with her abrupt change in management from turnout to stabling. It was also found that she had sharp teeth which may have prevented her from chewing her fibre sufficiently. Both factors made her prone to impaction.

Ginger made a complete recovery and now has her teeth checked annually. When stabling is needed she is walked out regularly and fed soaked fibre.

EQUINE
Minster
VETERINARY CLINIC



Veterinary Surgeon Julian Rishworth

XLVets Equine Practice The Minster Veterinary Practice



Julian Rishworth BVetMed MRCVS, The Minster Veterinary Practice

Colic requiring surgical treatment

Oakley is a 10 year old part bred thoroughbred gelding, he first showed colic symptoms one evening, and his usual vets found an impaction of the pelvic flexure and treated it appropriately.

Unfortunately, Oakley continued to show signs of colic the following day, despite the treatment, which is not entirely unusual with impactions but what was unusual was the presence of distended loops of small intestine on rectal examination. When further treatment didn't resolve the colic and Oakley continued to display colic signs, the decision was made to refer Oakley for further investigations.

On arrival at the clinic, Oakley had a very mild elevation of heart rate and his temperature was normal but his respiratory rate was high at 40 breaths per minute. The colour of his mucous membranes (gums) was normal. There were still distended loops of small intestine on rectal examination as well as an impaction in the left colon. Scanning the abdomen showed the distended small intestine with more fluid surrounding the intestines than would normally be expected. A sample of this fluid was obtained from the lower part of the abdomen and this showed that the fluid was more red and cloudy than normal; the normal fluid should be pale yellow and clear. This was sufficient indication that there was a problem in the abdomen that needed surgery to correct but further blood tests helped confirm this and in particular the lactate levels showed that there was a reasonable prognosis for a problem that could be corrected by surgery.

Oakley was prepared for theatre immediately by placing a catheter into the jugular vein in the neck, and antibiotics and pain relief were

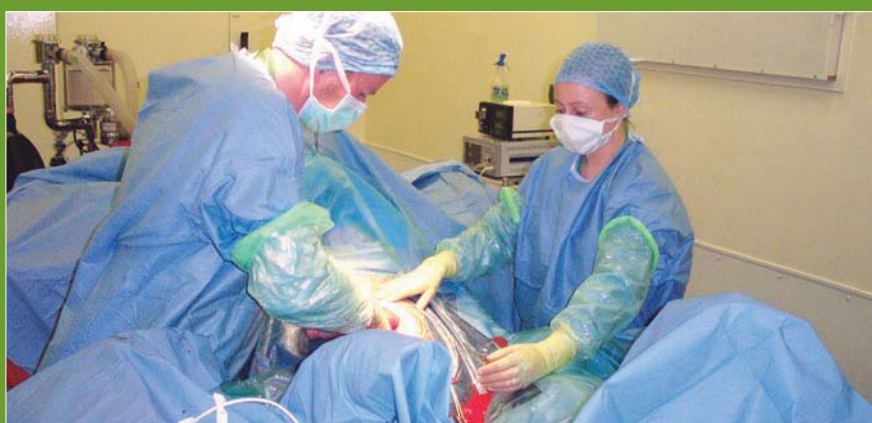

Oakley

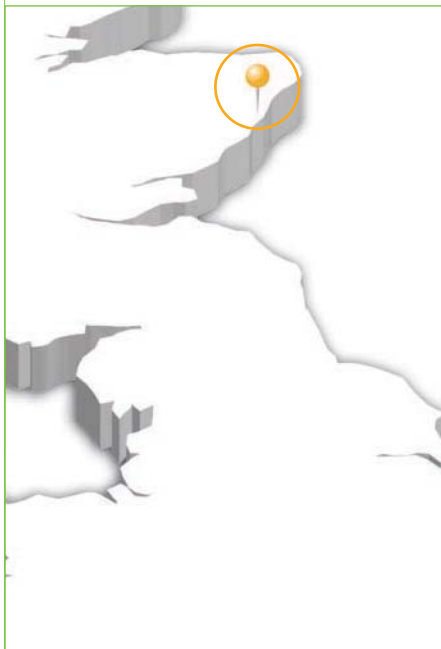
given before the start of surgery. Oakley was anaesthetised and on the surgical table within about one hour of his arrival at the clinic.

The surgical incision is made in the midline base of the abdomen, just in front of the umbilicus (belly button). Once in the abdomen, the loops of distended small intestine were obvious but the caecum was very empty. The problem was identified as a twist in the last part of the small intestine. This had slowed the passage of food material and partly compromised the blood supply to this section of the bowel. This had resulted in the small intestinal wall swelling, further stopping food material completely, hence the empty caecum and impacted material in the large bowel, deprived of the important fluid which would normally come from the small intestine.

Surgery was performed to remove the damaged section of small intestine and create a new 'join' between the new end of the small intestine and the caecum. In all, Oakley had 16 feet of small intestine removed in a surgery that took just under three hours. After replacing the repaired intestine back into the abdomen and repairing the abdominal incision, Oakley made a good recovery from anaesthesia. Post-operative recovery was unremarkable. After seven days in the clinic with antibiotics, pain relief, intravenous fluid therapy and a careful re-introduction to feed and water; Oakley was discharged back to his owners for a further three months box rest to allow the surgical wound to fully heal. Oakley's case is a good example where prompt decisions by his regular vets to recognise that this was more than a regular pelvic flexure impaction meant that surgery was more likely to be successful with fewer complications.

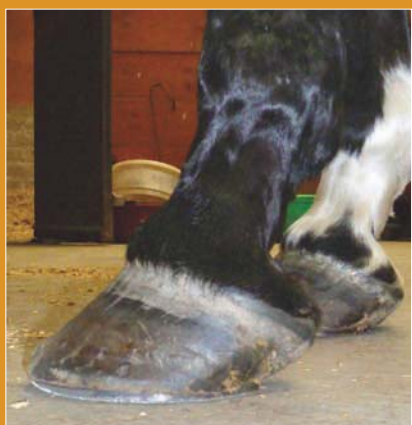

Oakley had 16 feet of small intestine removed at surgery



Veterinary Surgeon **Graham Hunter**

XLVets Equine Practice **Ardene House Vet Practice Ltd**



A long toe low heel conformation. This horse is shod with poor support at the back of the foot

Graham Hunter BVM&S GPCert(EqP) CertEP CertAVP(ESO) MRCVS,
Ardene House Veterinary Practice

The foot as a cause of lameness

Lameness can be described as a failure in normal motion with a deviation from the normal gait. Forelimb foot lameness is more common than hindlimb lameness. The centre of gravity of a horse is nearer the front of the horse and at certain times during the stride, huge forces are exerted down the limbs, through the foot to the ground. If we consider the small size of the horse's foot in relation to their body size, it is not surprising that foot lameness is very common.

The anatomy of the foot

Anatomically the foot is a complex structure with bones (pedal, pastern and navicular) and numerous tendons and ligaments that insert into these bones. The coffin joint includes a joint capsule and joint surfaces that are potential sites for inflammation. The navicular bursa is a fluid cushion which protects the deep flexor tendon as it runs over the navicular bone and can be involved

in some lameness cases. The laminae or interconnected 'fingers' are responsible for supporting a significant amount of the horse's weight and maintaining the pedal bone in the correct position inside the hoof capsule. Cases of foot lameness may involve more than one of these structures at a single time. These structures are mostly hidden within the hoof capsule so can be hard to visualise; therefore associated disease or injury can be difficult to diagnose.

Investigation of foot lameness

All investigations should begin with a good history where information such as recent injuries, changes in farrier, changes in feeding and exercise levels etc. can all be discussed. A visual inspection will evaluate the stance, conformation and symmetry; which can give vital clues to possible areas of trouble.

Palpation (feeling) of the limb and foot will be performed; heat or an increase in digital pulses can help in identifying foot inflammation. The pulses may be easiest to feel along the back of the fetlock and a comparison should be made with the opposite leg. The application of hoof testers, which are designed to apply pressure in selected areas of the foot such as the frog or sole, can help localise foot pain and may assist in diagnosing a bruised sole, an abscess, nail bind, laminitis or heel pain.

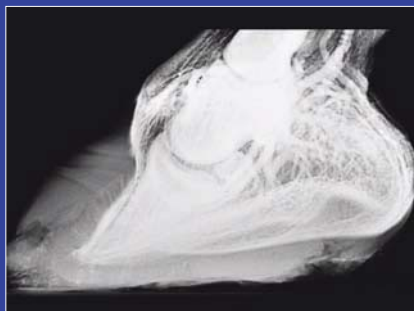In cases where the source of lameness is unclear or needs confirmation the next step is the localisation of the pain using a nerve block or joint block. Local anaesthetic is placed around a nerve or into a joint or bursa to numb the area. Once an area is 'blocked'; if the horse becomes sound we then know that area is relevant to the cause of the lameness. We then need to image the area to identify any abnormalities. This is most commonly done using x-rays. We can visualise fractures, navicular degeneration,

osteoarthritis in the coffin joint, pedal bone changes such as pedal osteitis or changes in position of the pedal bone such as in laminitis. Sometimes if the lameness is caused by damage to soft tissue structures, very little may be seen on the x-rays and other imaging techniques need to be used.

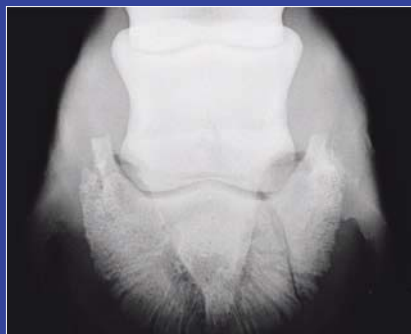Many other different techniques are used to look at different tissues and structures in the foot. Ultrasound imaging can be used as well as nuclear scintigraphy (bone scan), magnetic resonance imaging (MRI scan), computed tomography (CT scan), thermography and contrast venography.

Investigation of foot lameness may involve:

- history
- visual examination
- palpation (hands and hoof testers)
- nerve and joint blocks
- radiography
- contrast venography
- ultrasound
- nuclear scintigraphy (bone scan)
- MRI
- CT
- thermography



Contrast venogram of a chronic laminitic foot showing good circulation



X-Ray showing a pedal bone fracture

The treatment and management of foot lameness

Treatment of foot lameness obviously relates to the cause. In some cases specific treatment may be indicated e.g. a foot abscess needs to be drained and poulticed. No matter what the diagnosis is, in foot lameness cases and indeed many other causes of lameness, foot trimming and balancing are fundamental to successful resolution of lameness.

Medical treatments used include joint or bursal injections of anti-inflammatories or compounds which assist with joint repair and maintenance; these can be used in cases of coffin joint or navicular bursal inflammation. Tiludronic acid can be used in cases where alteration in bone modelling is required, such as in some navicular disease cases. Oral anti-inflammatory pain relief such as 'bute' will also frequently form part of treatment protocols in horses with foot lameness.

Surgery may be performed to obtain more information as well as used in treatment. Coffin joint arthroscopy and navicular bursoscopy can be used to see inside these synovial structures helping to visualise damaged or affected tissue. During surgery 'tidying up' of damaged tissue can also be performed. Other surgical procedures may include cutting out of tissue, such as keratomas (a type of benign tumour within the foot) or infected areas of pedal bone. As a last resort, neurectomies can be performed i.e. cutting nerves to remove pain sensation from the feet of chronically lame horses.

Diagnosing the foot as the cause of the lameness is relatively straight forward; yet identifying affected structures and tissues with reliable specificity remains the challenge. Fortunately treatment strategies have improved and diagnostic procedures exist now which can help solve even the most elusive of problems. Most foot lameness, even when originating from the navicular region; does not carry the poor prognosis that was previously given in these cases. Early diagnosis and perseverance in treatment is frequently the key to success.

Examples of surgical treatments used in foot lameness:

- palmar digital neurectomy;
- desmotomy of the collateral ligaments of the navicular bone;
- desmotomy of the inferior check ligament;
- arthroscopy of the coffin joint;
- bursoscopy of the navicular bursa.

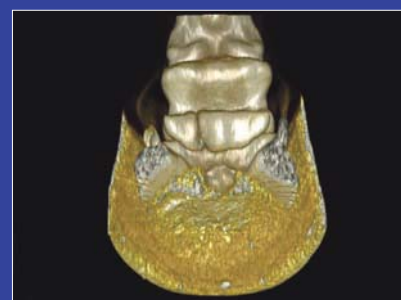
Examples of non- surgical treatments used in foot lameness:

- foot trimming;
- remedial farriery;
- NSAIDs (e.g. 'bute');
- injection of corticosteroids, hyaluronic acid, or regenerative therapies into the coffin joint or navicular bursa;
- tiludronate;
- isoxuprine;
- intramuscular joint therapy;
- extracorporeal shock wave therapy.

A few examples of causes of foot lameness:

- nail bind/prick;
- foot imbalance;
- foot abscess;
- thrush;
- solar bruising;
- corns;
- sheared heels;
- canker;
- puncture wounds;
- coronary band and hoof wall lacerations;
- quittor;
- pedal bone fractures;

● navicular bone fractures



● hoof wall cracks



- hoof wall separation (white line disease);
- pedal bone infection;
- keratoma;
- navicular disease;
- coffin joint osteoarthritis;
- laminitis;
- deep digital flexor tendonitis;
- coffin joint collateral ligament injury.




MRI of the equine foot

MRI (magnetic resonance imaging) is an advanced imaging technique that produces highly detailed cross sectional anatomical images of bone and soft tissue structures in the area being examined.

The images are obtained by placing the area to be examined in a magnetic field. This area is then bombarded by a series of pulses of radiowaves. The signal is received back by a coil within the machine which converts them into a series of 3D images. The procedure is low risk to the patient and handlers because ionising radiation (used in radiography and bone scans) is not used.

Types of MRI imaging

MRI can be 'high field' using very high magnet strength, which produces the most detailed images; however the horses need to be given a general anaesthetic to go into these machines. The majority of equine MRI imaging done in the UK is 'low field' (using a weaker magnet) but the units are designed for horses to be able to walk in and be examined under sedation.



Horse standing in MRI

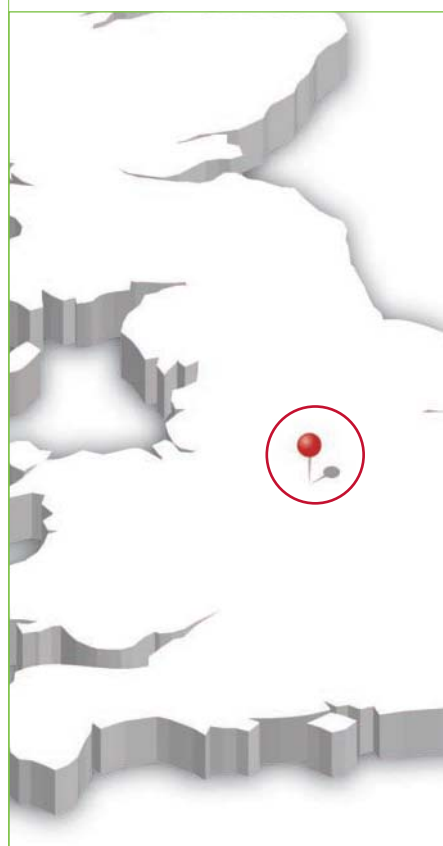
The indications for an MRI examination

Only small areas can be examined for an MRI study so it is not realistic to obtain images of a whole leg. It is therefore important that the lameness has been clearly isolated to the foot region using nerve or joint blocks and that a standard set of x-rays have been completed prior to considering MRI imaging. In cases where changes in the bones or coffin joint are involved, a diagnosis may be made following x-ray examination. MRI is a useful tool for further investigation where significant x-ray changes are not present or if the horse remains lame despite initial medical therapy.

MRI allows assessment of the bones and cartilages within the foot and can be useful in diagnosing the following foot conditions:

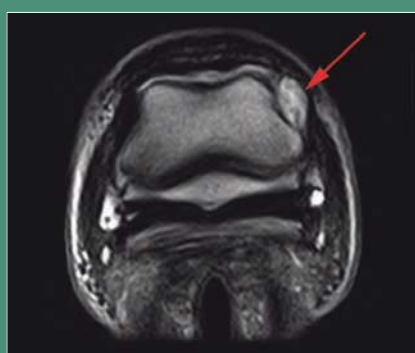
- changes to the navicular bone structure;
- damage to the deep digital flexor tendon;
- damage to the small supportive ligaments of the navicular bone;
- injuries to the collateral ligaments of the distal interphalangeal joint (coffin joint);
- changes to the joints including the distal interphalangeal joint (coffin joint) and the proximal interphalangeal joint (pastern joint).

MRI is a tool for diagnosis, not for treatment, and not every horse with foot pain needs an MRI. It will however help to give an accurate diagnosis of what structures are involved in causing a horse foot pain in cases where further imaging is indicated. A definitive diagnosis then allows your vet to discuss available treatment options and the likely prognosis of a return to soundness and function for your horse's condition.



Veterinary Surgeon Wendy Furness

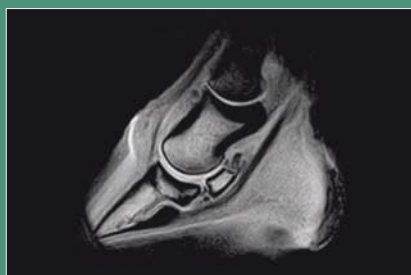
XLVets Equine Practice Scarsdale Veterinary Group



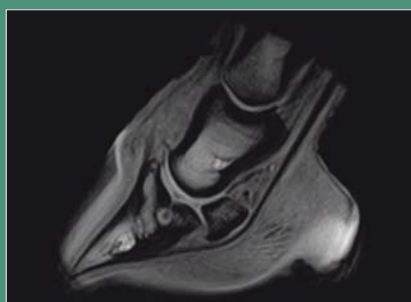
Transverse MRI image showing damage to the collateral ligament of the coffin joint

The advantages of MRI

The images obtained have excellent detail so offer a lot more information than conventional imaging techniques such as radiography and ultrasound. Ultrasound waves cannot pass through the hoof capsule so our ability to obtain good soft tissue images of the foot using ultrasound is very limited.

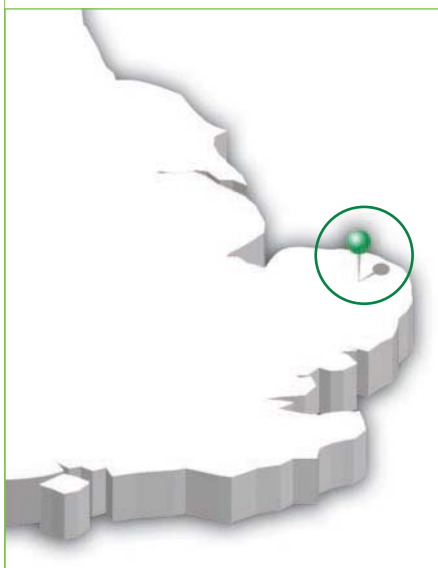


MRI image showing fragments on the border of the navicular bone



MRI image showing a bone cyst within the pedal bone

Chapelfield
VETERINARY
PARTNERSHIP



Veterinary Surgeon **Chris Lehrbach**

XLVets Equine Practice **Chapelfield Veterinary Partnership**



Chris Lehrbach BVMS MVM Cert ES(Orth) MRCVS,
Chapelfield Veterinary Partnership, Brooke Equine Clinic

Foot balance explained

Whilst advances in science have resulted in the occasional reports of equine prosthetic lower limbs, which would undoubtedly have saved the patient's life, without a foot there is still generally no horse. One particularly problematic aspect of the horse's foot is its shape, a feature of its conformation termed the foot balance.

Put simply, the assessment of foot balance is generally carried out initially by visual inspection in the resting, weight bearing position on a firm level surface from the side, from in front and from behind. The foot can also be viewed from above when it is picked up and, with the sole perpendicular to the ground, the side to side balance or medio-lateral (M-L) balance can be assessed. The use of an instrument called a T-square can also help gauge any imbalance.

A side view of the foot is aiming to assess the alignment of the hoof wall at the toe, relative to the hoof wall at the heel and to the angle of the pastern bones up to the fetlock joint. This is termed the hoof pastern axis (HPA). The normal acceptable range of angle is roughly 45-50° for forelimbs and 50-55° for hindlimbs, with some breeds such as the TB being slightly less, while a Cob for example might be expected to have a more upright angle. Ideally, a straight line should be able to be drawn from the toe, along the front of the pastern to the fetlock (Figure 1).

A horse with an upright or broken forward HPA would have a shallower pastern angle compared with the front of the hoof wall and would tend to occur in animals with boxy or clubbed feet (Figure 2). In contrast, a horse with a broken back HPA would have a steeper pastern angle (Figure 3) and can be seen in animals with long toes and collapsed heels.

Both these abnormalities can predispose to injury and associated lameness if uncorrected.

When viewed from in front, behind or above (Figure 4) with the foot elevated, the M-L balance can be assessed. The M-L foot shape should normally be more or less symmetrical, although many horses are not perfect. M-L imbalance can result in the hoof wall and coronet being higher on one side than the other (Figure 5), or the quarter/toe wall growing out at a different angle from the other side, causing the foot to 'drift' inwards or outwards. Any M-L imbalance will become self-perpetuating as the hoof wall will tend to grow in the direction of the imbalance. The consequences of M-L imbalance are an alteration in the distribution of weight bearing forces passing through the foot and limb, resulting in tissue injury and lameness within the foot and further up the limb.

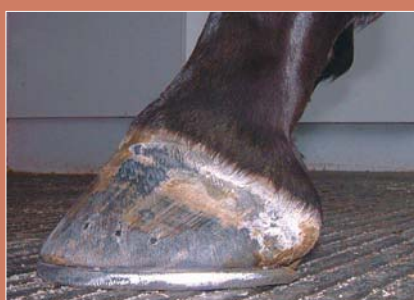

Figure 1. A normal hoof pastern axis, the front of the hoof wall and pastern area being aligned

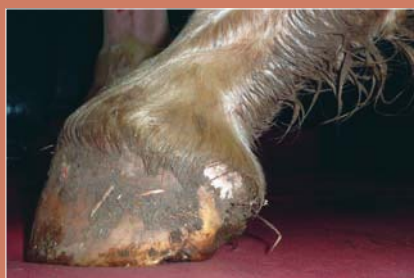

Figure 2. A broken forward hoof pastern axis, with upright hoof wall

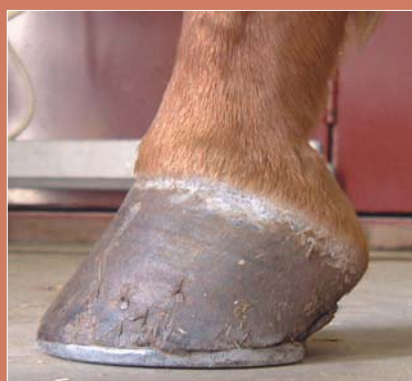

Figure 3. A broken back hoof pastern axis, with upright pastern compare to hoof wall

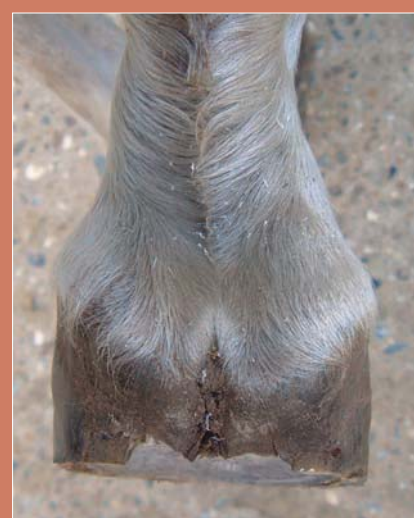

Figure 4. Side to side foot imbalance viewed from above, with asymmetry of the hoof wall



Figure 5. Side to side foot imbalance viewed from in front, with one side of the hoof wall higher than the other



Trimming and shoeing for long-term soundness

R J Chard DipWCF(Hons) AWCF, Mid Sussex

Many years ago when I was doing a farriery demonstration, I was asked by a member of the audience, 'is the hoof really made of wood?' After taking a deep breath and realising that this was a serious question, I replied 'I wish it was, because it would make my job a lot easier!' The equine hoof although being tough and resilient can also be weak and vulnerable through many factors placed upon them by us humans.

The evolution of farriery

The modern horse we know today has evolved over millions of years, surviving quite happily without human intervention, with regards to hoof maintenance. In a natural environment, horses graze varied terrain and so wear away the excess hoof growth keeping the hoof at a constant length and negating the need for intervention. If the horn wasn't worn away in time with its growth, the hoof would bend and distort under the horse's own body weight. Not too much of a problem perhaps over a short time, as long as normal activity levels returned and the growth/wear equilibrium restored.

Very few of our horses today have the privilege of self maintaining their own hooves, hence the need for human intervention. Additionally, more and more horses are being bred for performance alone and the way in which the modern equine is maintained and managed, means that hoof care and ultimately their soundness is even more important than ever.

Understanding hoof structure

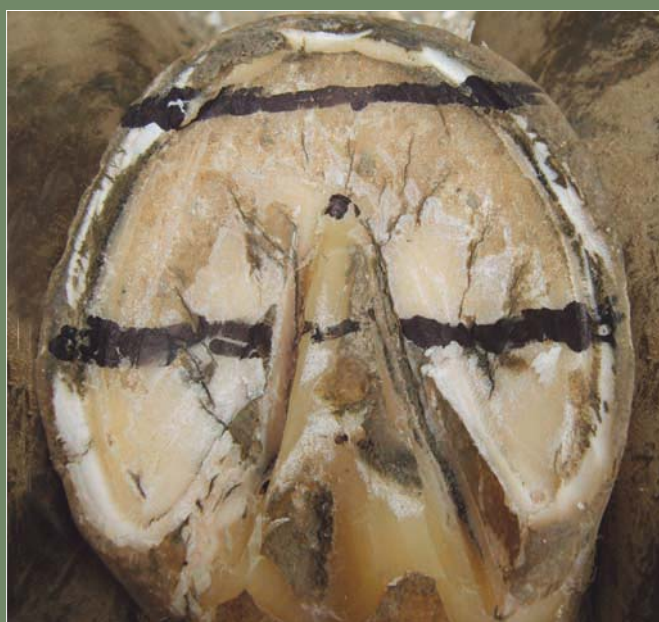The hoof is made up of many tiny tubes (called horn tubules) that when packed together form a very strong horny capsule around a similarly shaped bone inside which is attached to the rest of the skeleton. The hoof capsule is a perfectly adapted structure to support and enable locomotion for the equine, however out of its natural evolutionary habitat it can suffer.

Think of the bone within the hoof (P3 or pedal bone) as the foot itself and the hoof around it as a protective covering, just like we would wear a pair of trainers. To get the maximum performance out of this unit the hoof must fit perfectly around the bone. Just like our well fitting trainers that are not only supportive but also allow us to comfortably run, jump and turn at speed, the hoof capsule can do all of that if maintained properly and kept 'in balance'.

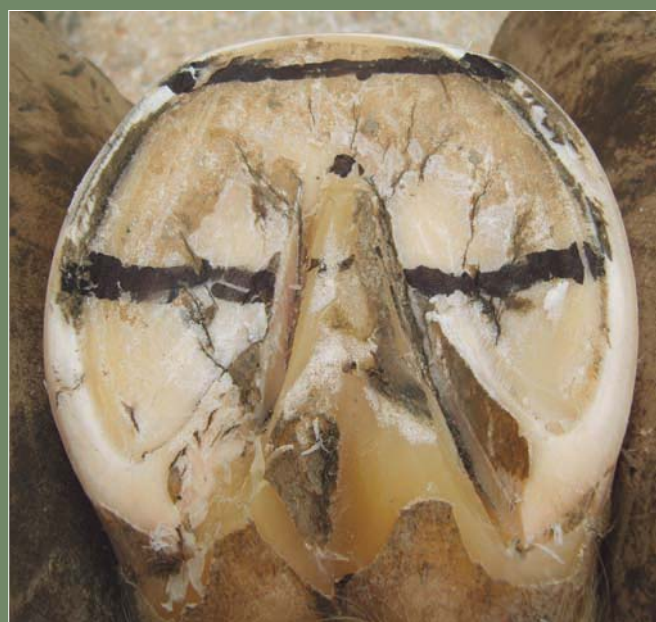A horses' conformation is such that from the fetlock down the limb is projected forward



along with the hoof capsule and not straight down like a post. This means that as the hoof grows longer it also grows more forward thus increasing the overall length from the fetlock. Small increases in its length are probably within the equines' acceptable tolerances. However larger increases in length possibly coupled with distortions that may have formed, when put under the stress of athleticism, can have devastating and potentially long term effects on soundness both within the hoof and in structures further up the limb. Applying horse shoes to an overgrown/distorted hoof further escalates these destructive forces.



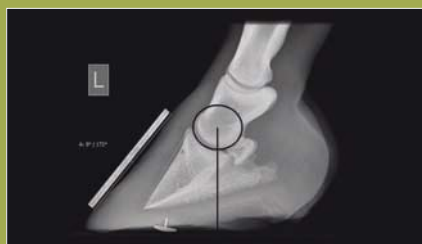Hoof map prior to trimming



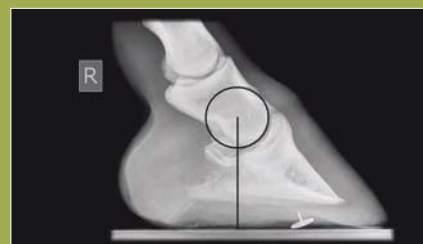Hoof map after trimming

What is balance?

Balance is the state whereby the hoof wall, sole, frog and bars are prepared so that an equilibrium exists around the DIP joint (pedal joint), with a shoe placed on the foot, providing maximum base of support while still minimising stresses and leverages to the lower limb, both statically and dynamically.



Unequal loading



Equilibrium

Identifying and correcting hoof distortions

We know that as the hoof grows and lengthens, structures like the wall, bars, frog and sole are likely to deform due to the mass of the horse that is standing on them. This can be exacerbated by conformational defects and environmental situations i.e. weather and conditions under foot. Under damp conditions, the horn tubules that make up the hoof become soft and more pliable therefore subject to greater distortions. Modern breed types also contribute to the situation as solid strong hooves do not seem to be at the top of the breeding wish list.

For the most part, recognition of these distortions is the most important aspect of modern hoof care, without the ability to identify the distortions present in the hoof they cannot be corrected. The challenge is relating the outside of the hoof to the structures inside i.e. P3/pedal bone. We cannot see inside the hoof, without an x-ray, which is not practical to do on every horse everyday!

In recent years a group called the Equine Lameness Prevention Organisation (ELPO) and others have developed an accurate method

of mapping out the under side of the hoof using 'landmarks' that remain constant in relation to the position of P3/pedal bone within the hoof. Their method of identifying and dealing with hoof distortions has taken away the guesswork in trimming and the positioning of a shoe to optimise the hoof's performance. Armed with this knowledge it is now possible to be much more precise in 'balancing' the hoof, this can only be of massive benefit to our equine athlete's long-term soundness.



Excessive distortion



Hoof with excessive distortion showing correct shoe placement



Dr Teresa Hollands BSc(Hons), MSc(nutrition) PhD R.Nutr

Senior Nutritionist, Dodson & Horrell Ltd (official supplier of nutrition to The British Equestrian Team) and Specialist Lecturer, University of Nottingham School of Veterinary Medicine and Science

Feeding for performance

Each of us has a different expectation of what we want to achieve with our horses and therefore need different nutritional support for ourselves and our horses. We need our horses fit enough to compete with others of a similar standard whether at World Class or local show level. Equine and human fitness and nutrition are linked; how many of us know forty to fifty year olds that are much fitter now than when they were in their teens, partly as a result of being more nutritionally savvy?

We take nutrition very much for granted as it is difficult to measure the effects of both short and long term imbalances. However as our team vet stated 'it only takes a 1% improvement in performance to move us from silver to gold' and how right he was.

Athletes take their nutrition seriously, their back up team always includes a nutritionist; and so should equine athletes (both horse and rider). Unlike many sports, there are two of you in the equation; you and your horse, both of whom need balanced nutrition; it is surprising how much in common we have with our horses when it comes to nutrition.



Eat regularly

You:

- eat breakfast so you remember that dressage test or the jump off course. Harvard University showed that students who ate breakfast had better concentration compared with students who rarely ate breakfast.



Your horse:

- about 80% of sports horses have gastric ulcers. American scientists measured the acidity within horses' stomachs and found horses fed breakfast two hours before exercise, had smaller amounts of damaging acid in the top part of their stomachs compared to horses fed after exercise. Acid in the upper stomach increases the risk of gastric ulcers reducing performance.



Carb Charge

You:

- carbohydrates are an excellent source of fuel. Cutting back on carbs isn't a good idea for athletes, because it delays muscle recovery and reduces glucose for concentration. Good sources of carbohydrates include fruits, vegetables, and whole grains. Sugary carbs e.g. chocolate and fizzy drinks are just empty calories because they don't contain any of the other nutrients you need. Sugary snacks will give you a quick burst of energy but then you 'crash' or run out of energy before the end of your competition or training.

Your horse:

- horses obtain fibre (a structural carbohydrate) from more than just forage; whole grain cereals provide them with fibre and carbohydrates. All competition horses probably need some carbohydrates; the faster the horse works, the more they need starchy carbohydrates. Many endurance horses are unable to maintain the speeds needed with the conventional diet of fibre and fat. Your horse needs carbohydrates to replace the glycogen he burns in his muscles; feed small meals (<1.5g starch/kgBW/meal) to maximise small intestine digestion for recovery and to stop undigested starch reaching his hind gut. Feed within 1hr of finishing exercise, to maximise glycogen replenishment.

Energising electrolytes

You:

- research showed sports drinks are no better for you than water unless you are exercising for more than 60 to 90 minutes, or in hot weather, when the additional carbohydrates and electrolytes may improve performance. Recent research showed that milk is one of the best 'electrolyte/energy' drinks; containing protein, carbohydrates and electrolytes.

Your horse:

- the correct ratio of forage fed with the recommended levels of a good competition feed, provides your horse with his daily electrolyte requirements. However if he regularly sweats heavily, add up to a tablespoon of salt to his feed daily. If he loses more than 10% of his bodyweight during competitions, he needs additional electrolytes.

Diminish dehydration

You:

- water is as important as food in unlocking your riding potential. How much fluid you need depends on your age, size, level of physical activity, and environmental temperature. Mild dehydration affects physical and mental performance; 75% of people are chronically dehydrated; it is the primary cause of daytime fatigue ...maybe the difference between first and second place at a competition?
- should drink before, every 15 to 20 minutes during and after exercise. Don't

wait until you feel thirsty, thirst is a sign that your body has needed liquids for a while.

Get into the habit of weighing yourself before you ride (yup with all your gear on) and again when you finish; for every 1kg you lose, you need to drink one litre of water. Start now to get your body trained, not the first day of this season's competitions...or you'll need 'to go' half way down the centre line.



Your horse:

- post-competition weight loss is due to dehydration in the horse (D Marlin). Our research at Burghley showed that some horses lost as much as 23kg after the dressage test - yes after dressage! Teach your horse to drink from a bucket as you start to get them fit; on the lorry and in the stable. Flavour the water so they don't taste the difference at the shows.

- Never give electrolytes to a horse which is not drinking or dehydrated. A high gut electrolyte concentration pulls more water out of the blood increasing the dehydration of the body.

Ten ways to combat dehydration:

- feeding hay four or five hours before competitions increases his reservoir of water;
- if it is hot allow the horse to have small drinks of water (4-5 litres) and electrolytes during the competition;
- give electrolytes for two to three days after a competition if the horse has been sweating hard;
- use cold water cooling; a horse with a rectal temperature of 40°C needs 180 litres of water to effectively cool their body;
- if it is hot, then 'warm up' in the shade;
- use a weigh tape to monitor dehydration weight changes;
- maintain correct body condition, a fat horse will dehydrate quicker than a fit horse;
- travelling can result in dehydration; feed and water regularly;
- encourage higher water intakes by making feeds sloppy; add succulents;
- check your dose of the electrolytes provides adequate salt, potassium, calcium and magnesium.




Nutritional support and training must be based on sports science and considered together. Feeding the horse is an intricate balance between the art of feeding and science. Some will argue that the horse with the big heart will always beat the horse with the talent. But just think if we could make more of the science just how that balance might tip.



Peak Performance: Eventing:

We asked the experts for tips on achieving peak performance in eventing



Veterinary Surgeon **David Rowlands**

XLVets Equine Practice **Penbode Equine Vets**



David Rowlands BVSc CertEM MRCVS, Penbode Equine Vets

What are the common veterinary problems of the event horse and how can they be prevented?

Eventing is probably the most all round test of a horse's athletic ability. Event horses are generally four to five years old (skeletally mature) when they start training so tend not to develop the same bone issues that trouble young racehorses. The amount of endurance training necessary produces repeated cyclic loading, hence problems such as osteoarthritis and tendonitis are common. Acute traumatic injuries can be sustained during competition. Falls sustained by hitting fixed obstacles at speed can result in direct traumatic fractures.

The prolonged period and intensity of training required for horses to reach an elite level often leads to horses with underlying metabolic or certain physical issues not making it to the top, e.g. few elite eventers have recurrent exertional rhabdomyolysis (RER) or navicular syndrome.

Ten common lameness conditions seen in event horses:

- 1 back and neck soreness and restriction;
- 2 foot soreness (bruising and imbalance);
- 3 traumatic osteoarthritis (coffin joints, fetlocks, hocks, pasterns);
- 4 superficial digital flexor tendonitis;
- 5 suspensory ligament desmitis (branches or proximal);
- 6 external trauma (lacerations, penetrations and stifle bruising);
- 7 pain in sacroiliac region;
- 8 fractures of the stifle region;
- 9 other fractures;
- 10 recurrent exertional rhabdomyolysis (RER).

Prevention of lameness

To optimise performance and reduce injuries, event yards need to function as an effective team. At the centre of this team are the rider and horses and in support are the trainers, vet, farrier, physiotherapist and nutritionist. Good communication and a unified approach are essential.

Correct conformation can help reduce the incidence of many lameness issues. Don't underestimate the importance of a pre-purchase examination (vetting) to help start out with an appropriate horse. Foot conformation is particularly important. An experienced farrier in conjunction with your vet will help optimise foot balance and shoeing.

Appropriate riding surfaces, training and competition programmes are important; designed to achieve fitness and experience whilst minimising the risk of injury. The incidence of RER can be reduced by optimising exercise and nutrition via communication between with the nutritionist, trainers and vet. Back pain can be alleviated by a master saddler regularly checking saddle fit, and examinations and treatment by your vet and physiotherapist.



Lizzie Drury MSc, registered nutritionist, Saracen Horse Feeds

Top tips for feeding for eventing peak performance

Training:

- Daily forage intake for event horses should not fall below 1.5% of bodyweight. Hygienically clean grass hay or haylage helps to maintain respiratory health.
- Concentrate feeds should provide a variety of energy sources e.g. starch (provides power and aids glycogen replenishment), digestible fibre and oils (support stamina and hydration).
- Feed electrolytes (Na, Cl, K, Ca and Mg) pre and post exercise along with water to maintain hydration.

Fortnightly

- Monitor and record your horse's body weight and body condition score (BCS). This can help you to achieve optimum competition 'fighting' weight. The ideal BCS for event horses is 2-2.5 (scale of 1-5).

Competition day

- Alfalfa is natural antacid. Frequent bites of chaff help to neutralise excess stomach acid due to intermittent feed regimes on competition day.
- Cereal feeding alone should be avoided for at least four hours to prevent insulin spikes and energy depletion. Instead feed a small chaff meal (1 lb) prior to exercise.

Charlotte Rowe, Charlotte Rowe Eventing, Tedburn St Mary, Devon
Professional event yard manager and rider

In the sport of eventing how do training and talent influence 'peak performance'?

In the sport of eventing the partnership of horse and rider is put under a series of challenges: maintaining calm control in the dressage, accuracy in the show jumping ring and courage and athleticism in the cross country phase. In looking for a future top horse straight accurate movement is essential if the horse is to stand up to the rigours of training and competing; but they also need to be clever, nimble and shout 'look at me'. However, I find a kind and easy temperament the most important quality as this dictates their 'trainability' which can determine their future success.

In training I believe that variety is essential to prevent boredom. Each week my horses are schooled twice, the other four days a different exercise is used; lunging, cantering, jumping and hacking and the seventh day is a rest day (we all need one!).

Whilst at home variety is key, at competitions I try to keep the routines the same in terms of the type and amount of warm up, this helps to keep the horse and rider calm as the consistent routine feels familiar despite the different surroundings.

For horses competing at the top levels the stresses and strains of competition must be balanced with the need to gain competitive experience and maintain fitness. My top horses do not compete more than eight times in a season and need a longer recovery period following competition.

Despite riding eight to ten horses a day I also run twice a week, it is vitally important that even at the last fence after a long day I could make a quick decisions and act on it to help protect myself and the horse from injury.



Stuart Taylor DipWCF, Stuart Taylor Farrier Ltd. Exeter, Devon

What role does farriery play in achieving eventing peak performance?

Eventing is the most advanced level of competition where three disciplines are combined. So by trimming the horse correctly and shoeing with symmetrical balanced shoes you are giving the horse every chance to achieve optimum performance. Whilst all horses and ponies deserve the utmost accuracy when foot trimming, the eventer does require more attention to detail with respect to foot balance. I recommend a shoeing interval of four to five weeks for the top level horses this allows me to

maintain accurate balance and prevent foot overgrowth and deviation. Quick and accurate digital x-rays can help make certain the horse is trimmed and then shod to the absolute millimetre perfect foot balance.

There is a massive amount of grip that can be obtained just by using a well fitted balanced concave shoe but extra grip under slippery conditions can be achieved by using preferably two studs in each foot.

Having gone to great lengths to trim the horse correctly and fit a well-balanced symmetrical shoe, using one stud can defeat the object of being balanced and symmetrical.

A good working relationship between client and farrier can help identify and rectify problems in the lead up to competition and allow adjustments to be made between competitions. Working together we can help the horse to achieve 'peak performance.'



Foot conformation: What to look for

Richard Sutcliffe BVM&S MRCVS, Bishopton Veterinary Group

Good foot conformation relies upon the following:

Symmetry

Both front and back feet should be matching pairs in size and shape. They should have the same height of heel and matching dorsal wall angles (front feet approximately 45° ; hind feet approximately 60°) and each hoof should also be symmetrical about its mid-line with no flaring of the hoof capsule to the inside or outside.

Straight hoof pastern axis

A 'broken back' (fig.1) hoof-pastern axis is usually seen with a long toe: low heel conformation and will result in caudal heel pain. 'Broken forward' (fig.2) hoof-pastern axis can occur with abnormally sloping pasterns or as a consequence of contraction of the flexor tendons during the growth of youngsters. Both are undesirable and a cause of weakness.

nail into. Horses with poor quality, flaking or crumbly horn will be very difficult to keep shoes on and will suffer repeated bouts of lameness. Horn disease such as seedy toe or canker will also predispose to lameness.

Even horn growth

An evenly growing hoof capsule is smooth; conversely, marked changes in nutrition result in surges of horn production which cause ridges to develop on the surface of the hoof ('grass rings'). These should not cause concern. If ridges diverge towards the heel, however, they signal chronic laminitis and frequently occur in association with a concave dorsal wall. If inspecting feet, check for rasp marks over the upper hoof wall as this may be a sign that abnormal growth rings have been rasped away.

Concave sole

The solar surface should have a good degree of concavity. The sole should be firm and not too thin. Flat feet with little concavity will lead to bruised soles. A dropped sole may occur in laminitic animals where the pedal bone has rotated or sunk within the hoof.

Well-developed frog

The frog should be well developed with a shallow cleft. A deep cleft will predispose to thrush. A horse with 'shear heel' has a very deep cleft and the inner and outer heels will be of unequal height and can be flexed independently - often painfully.

Healthy white line

The white line is where the horn of the hoof wall and sole meet and it is an area of weakness which, if breached, can allow bacteria into the sensitive structures leading to 'pus in the foot' or 'gravel'. Laminitis will cause widening of the white line exaggerating the weakness of this area. Another cause of weakness in this area is a keratoma (a benign, horn-producing tumour of the foot) which can be recognised when it produces a defect or deviation in the white line on the sole.

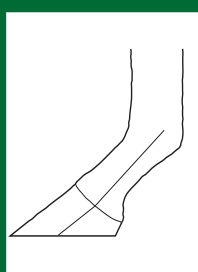


Figure 1

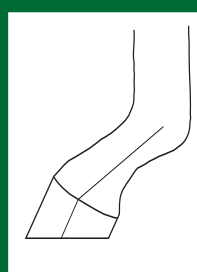


Figure 2

Level footfall and good medio-lateral balance


Medio-lateral balance is best assessed with the limb non-weight bearing. An imaginary line down the cannon and pastern should cross the bearing surface of the sole at 90° . Sometimes a compromise has to be reached between trimming for good medio-lateral balance and achieving level footfall. Unequally worn shoes are a sign of abnormal footfall.

Straight dorsal hoof wall

The wall when viewed from the side should be straight - neither concave nor convex. A concave dorsal wall occurs in chronic laminitis.

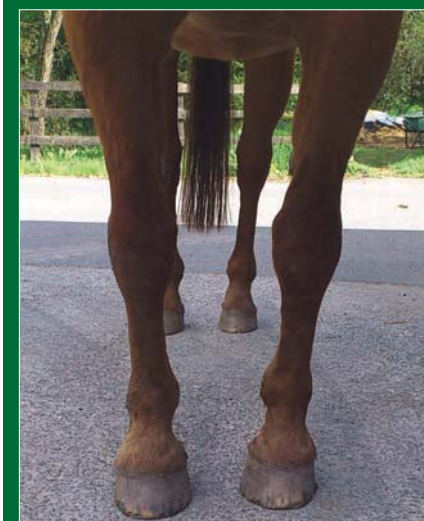Good horn quality

The hoof horn quality needs to be good to ensure protection from bruised sole and to provide the farrier with a strong material to



Veterinary Surgeon Richard Sutcliffe

XLVets Equine Practice Bishopton Veterinary Group



Mediolateral imbalance



VET VIEWPOINT...

WE VIEW THE OPINIONS OF OUR VETS ON WHY FOOT PROBLEMS ARE STILL VERY PREVALENT IN HORSES.

Neaera Fletcher
BSc(Hons) BVMS MRCVS
Paragon Veterinary Group



The horse's foot has evolved into a single weight-bearing digit, designed for speed and the ability to bear the load of the horse through the limb. 'no foot, no horse' maintains the same importance today, as it did when the saying was first used. If not resolved promptly, damage to the foot can be catastrophic for a horse. Horses are too heavy to manage on three legs; the amount of stress applied to the ligaments, tendons and joints of the uninjured weight-bearing limb would become overwhelming. Domesticated horses rely on us, their owners, to maintain the integrity of their feet through daily care, regular trimming, maintaining correct balance and shoeing where appropriate. With around 80% of lameness cases originating in the foot, it is a crucial part of the horse which deserves the attention and care that the saying 'no foot, no horse' suggests.

Does the old saying 'no foot no horse' still apply today?

Claire Sawyer BVet Med Cert AVP(EOS) MRCVS
Wright & Morten Veterinary Surgeons



Absolutely! Foot problems are still very prevalent in horses, and even if a horse doesn't have a primary foot problem; foot balance can affect the rest of the limb and even the back and neck.

Everyone has always talked a lot about front feet, which are very important...but back feet should not to be forgotten. Hind foot balance is just as important as front foot balance in keeping horses sound. If a horse has long toes and collapsed heels it is said to be flat footed - this imbalance puts additional strain through the rest of the limb. Flat hind feet are particularly problematic in horses with hock pain - especially bone spavin and suspensory problems.

Imbalance in the hind feet can cause the horse to load joints unevenly and tense up through the back potentially resulting in back pain, joint injuries and behavioural problems.



Jane White BVetMed GPCert(FEiP) CVPhys MRCVS
St Boniface Veterinary Clinic

This was drummed into me as a child, perhaps to foster high standards of stable management and the need for regular farrier visits. It held true throughout my own Pony Club days first as a member then an instructor and when buying horses for competition. As a vet I find there is little to be gained in treating soft tissue problems without also addressing any foot issues.

What has changed over the years is the advance in the fields of remedial farriery and

nutrition. This means that many horses with poor foot conformation/balance can now be kept sound. Some laminitics that previously were euthanased may now be salvaged. The modern glue on plastic shoes and synthetic hoof materials benefit young foals through the correction of limb deviations.

A good farrier is worth their weight in gold to the welfare of our horses. So in the current economic climate foot care is one area I advise clients not to cut back on.



pony pages

Welcome...
TO THE SUMMER 2013
XLVETS EQUINE PONY PAGES



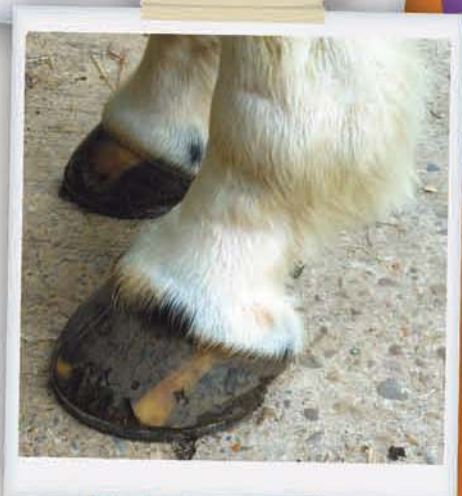Top Tips

FOOT CARE...

from Suzanne Naughton MVB MRCVS, Midshire Veterinary Group

**'No foot,
no horse'!**

- ✓ Pick out your pony's feet as often as you can. Remove any soil or loose debris and make sure to brush dirt out from the crevices surrounding the frog. This will keep your pony's hooves in good condition and reduce the likelihood of developing nasty foot infections such as thrush.
- ✓ Regular foot trimming is so important in keeping your pony's feet in tiptop condition. Normally the farrier should tend to your pony's feet every 6-8 weeks depending on how much work is done with your pony.
- ✓ Avoid turning your pony out onto wet muddy fields. This will affect the quality of your pony's hooves as well as increasing susceptibility to mud fever (this is a very sore skin infection). Or alternatively, try to fence off the worst affected areas in the field.
- ✓ Always monitor your pony's hooves for any changes such as heat over the hoof wall or a bounding digital pulse. The digital pulses can be felt at the back of the fetlock. Noticing these changes may help you in detecting painful conditions such as laminitis or a foot abscess, which may require your vet.
- ✓ Monitoring your pony's foot quality is very important. Keep an eye out for cracks that may develop, most cracks are superficial but some can be deeper and may require the attention of your farrier or vet. Some ponies may have poorer quality hooves and may require help from certain supplements, which contain biotin (an important component of the hoof wall).
- ✓ Try and keep your pony as fit and healthy as possible with regular exercise in order to keep its weight down. This in turn will promote normal blood flow in the foot and prevent the extra pressure on structures in the foot when excess weight is carried.





1st Competition page

ENTER TODAY

GOOD LUCK...

Welcome
XLVets Equine
Competition



YOUR CHANCE TO WIN!

Help 'Max'
to spot the
difference

How many differences
can you spot between
these two pictures.
Circle the differences
as you find them.
All correct entries
will be entered
into the draw
to win a great
grooming kit.



WIN an Equestrian Bag, containing
six items comprising a small body brush,
dandy brush, flick brush, face brush,
hoof pick and sweat scraper.

WIN!



The closing
date for entries is
**Friday 27th
September 2013**

Congratulations to competition
12 winner Amy Kinsella a client
of Westmorland Veterinary Group.

A winner will be chosen from all the correct entries received before the
closing date. The winner will be revealed in the next issue of Equine Matters.
The editor's decision is final, no correspondence will be entered into.

Send your completed entry to: Equine Matters Competition No.13
XLVets, Carlisle House, Townhead Road, Dalston, Carlisle, CA5 7JF

Name

Address

Postcode

Daytime Telephone Number

Email

XLVets Practice Name

- ☐ I do not wish to receive further information from XLVets
☐ I would like to receive further information from XLVets by e-mail

EXCELLENCE IN PRACTICE

XLVets Equine - Better Together

The members of XLVets have worked hard to create what they see as a model of how practices can work together, sharing the latest ideas and passing on savings and joint expertise to clients.

www.xlvets.co.uk

XLequine
Excellence in Practice

 608 Farm and Equine Veterinary Surgeons Rowington, Warwickshire Telephone: 01564 783404	 Cliffe Veterinary Group Lewes, East Sussex Telephone: 01323 815120	 Larkmead Veterinary Group Wallingford, Oxfordshire Telephone: 01491 651479	 Rosevean Veterinary Practice Penzance, Cornwall Telephone: 01736 362215
 Alnorthumbria Veterinary Group Morpeth, Northumberland Telephone: 01670 897597	 Clyde Veterinary Group Lanark, Lanarkshire Telephone: 01555 660000	 Midshire Veterinary Group Limited Nuneaton, Warwickshire Telephone: 02476 384064	 Scarsdale Veterinary Group Derby, Derbyshire Telephone: 01332 294929
 Ardene House Veterinary Practice Aberdeen, Grampian Telephone: 01224 740700	 Donald S McGregor & Partners Thurso, Caithness Telephone: 01847 892387	 Millcroft Veterinary Group Cockermouth, Cumbria Telephone: 01900 826666	 Scott Mitchell Associates Hexham, Northumberland Telephone: 01434 608999
 Belmont Veterinary Centre Hereford, Herefordshire Telephone: 01432 370155	 Drove Veterinary Hospital Swindon, Wiltshire Telephone: 01793 501499	 Minster Veterinary Practice York, North Yorkshire Telephone: 01904 788840	 St Boniface Veterinary Clinic Credon, Exeter Telephone: 01363 772860
 Bishopton Veterinary Group Ripon, North Yorkshire Telephone: 01765 602396	 Dunmuir Veterinary Group Castle Douglas, Dumfries Telephone: 01556 502400	 Northvet Veterinary Group Kirkwall, Orkney Telephone: 01856 873403	 Wensum Valley Veterinary Surgeons Fakenham, Norfolk Telephone: 01328 864444
 Calwetton Veterinary Group Callington, Cornwall Telephone: 01579 383231	 Endell Veterinary Group Salisbury, Wiltshire Telephone: 01722 710046	 Paragon Veterinary Group Carlisle, Cumbria Telephone: 01228 710208	 Westmorland Veterinary Group Kendal, Cumbria Telephone: 01539 722692
 Capontree Veterinary Centre Brampton, Cumbria Telephone: 016977 2318	 Fenwold Veterinary Centre Spilsby, Lincolnshire Telephone: 01790 752227	 Parklands Veterinary Group Cookstown, Northern Ireland Telephone: 028 867 65765	 Willows Veterinary Group Northwich, Cheshire Telephone: 01565 723030
 Castle Veterinary Surgeons Barnard Castle, Durham Telephone: 01833 695695	 Glenythorne Veterinary Group Uttoxeter, Staffordshire Telephone: 01889 562164	 Penbode Equine Vets Halsworthy & Okehampton, Devon Telephone: 01409 253418	 Wright & Morten Macclesfield, Cheshire Telephone: 08458 330034
 Chapelfield Veterinary Partnership Norwich, Norfolk Telephone: 01508 530686	 Hook Norton Veterinary Group Banbury, Oxfordshire Telephone: 01608 730085		

XLVets - We Excel