

XLEQUINE - BETTER TOGETHER

Equine

MATTERS


www.xlequine.co.uk

Inside this issue:

FOOT BALANCE

What we mean by foot balance and its impact on performance.

Angular limb deformities in foals



We discuss the assessment and treatment of angular limb deformities in foals

Vet Focus

In each issue of **Equine Matters** we feature a brief insight into a selection of the veterinary surgeons who make up XLequine. Featured in this issue are Claire Hodgson, Richard Morris and Sally Hodgson...



Claire Hodgson BVetMed CertAVP(EM) MRCVS



Claire Hodgson is a senior assistant equine veterinary surgeon at Wright and Morten Vets in Cheshire.

Claire joined Wright and Morten in 2002 as a mixed vet locum providing nine month maternity cover; three years later she left for a brief stint down south before being tempted back in 2006 to join the equine team and has been there ever since.

In 2012 Claire completed her advanced practitioner certificate in equine medicine and enjoys combining her interest in medicine with her stud work and managing the practice anaesthesia team. Most of her time is spent on the road looking after patients of all sizes, from miniature horses to Shires.

Outside work she is passionate about all things food and drink. When not in the kitchen or trying out the latest restaurant/bar, Claire can be found travelling the UK and Europe dancing the Argentine tango.



Richard Morris BSc BVetMed CertVD MRCVS



Richard Morris is one of three directors of the Fenwold Veterinary Practice in Spilsby in Lincolnshire.

Richard gained a BSc in Immunology and Pharmacology from King's College London in 1987 and qualified as a vet from the Royal Veterinary College in 1990. He has worked in farm, equine and small animal practice in the UK and New Zealand since qualifying and settled in Lincolnshire in 1996 where he became a partner of the Fenwold Veterinary Practice.

He is interested in all aspects of equine practice especially skin diseases and gained a Certificate in Veterinary Dermatology in 1996. He has written many articles in veterinary journals and presented talks to other vets on dermatological issues including sarcoids, allergic skin problems and Cushing's disease.

Outside work his spare time is devoted to enjoying quality time with his family, windsurfing on the Lincolnshire coast or mountain biking and horse riding in the Lincolnshire Wolds.



Sally Hodgson VetMB BA BSc MRCVS



Sally Hodgson is an equine veterinary surgeon at Hook Norton Veterinary Group in Oxfordshire.

Sally studied veterinary medicine at Cambridge as a mature student, qualifying in 2007 and specialising in equine practice straight away. Her first job was with a practice near Lambourn, working with sports and performance horses. She joined Hook Norton Veterinary Group in 2010, where she has a busy first opinion caseload as part of the dedicated equine team. Her particular interests are internal medicine, anaesthesia, lameness and rehabilitation after injury. She also organises and runs Equine Skills workshops and other client talks. Studying for a Certificate in Advanced Veterinary Practice keeps her knowledge and skills up to date.

Away from work she enjoys working her two spaniels in the shooting field and in dog agility, this year reaching team finals at Crufts! Other daylight hours are spent riding with friends - she is also learning to drive, with the aim of driving a four in hand team by the end of the year.

SPRING EDITION

XLEquine is a novel and exciting initiative conceived from within the veterinary profession. We are all independently owned, progressive veterinary practices located throughout the United Kingdom committed to working together for the benefit of our clients.

XLEquine member practices

608 Farm & Equine Veterinary Surgeons
 Alnorthumbria Veterinary Group
 Ardene House Vet Practice Limited
 Ashbrook Equine Hospital
 Belmont Veterinary Centre
 Bishopton Veterinary Group
 Calweton Veterinary Group
 Capontree Veterinary Centre
 Chapelfield Veterinary Partnership
 Cliffe Veterinary Group
 Clyde Veterinary Group
 Donald S McGregor & Partners
 Endell Veterinary Group
 Fellowes Farm Equine Clinic
 Fenwold Veterinary Practice
 Glenthorne Veterinary Group
 Hook Norton Veterinary Group
 Larkmead Veterinary Group
 Midshire Veterinary Group Limited
 Millcroft Veterinary Group
 Northvet Veterinary Group
 Paragon Veterinary Group
 Parklands Veterinary Group
 Penbode Equine Vets
 Rosevean Veterinary Practice
 Scarsdale Veterinary Group
 Scott Mitchell Associates
 Severn Edge Veterinary Group
 St Boniface Veterinary Clinic
 Wensum Valley Veterinary Surgeons
 Westmorland Veterinary Group
 Wright & Morten Veterinary Surgeons

Equine Matters is published by:

XLVet UK Ltd, Carlisle House
 Townhead Road, Dalston
 Carlisle CA5 7JF

Tel: (01228) 711788

*This publication is supplied free of charge to equine clients of XLVets member practices.

© XLVet UK Ltd

No part of this publication may be reproduced without prior permission of the publisher.

Disclaimer:

XLVets does not necessarily share the views of contributors. No responsibility can be accepted for opinions expressed by contributors, or claims made by advertisers within this publication.

THE EDITOR

Welcome to the 'Spring 2015' edition of Equine Matters...

...produced by XLEquine practices.

In this issue we focus on the equine foot with articles on foot balance, radiography of the equine foot and equine keratoma. We look at angular limb deformities in foals with a real life case study and a surgical feature.

We have chosen to discuss anti-doping regulations and their ability to maintain fair

competition as well as continue to provide an insight into XLEquine with three more featured veterinary surgeons.

On behalf of XLEquine I would like to wish you all a happy and healthy 2015.

Lee Pritchard BVSc MRCVS
 Calweton Veterinary Group

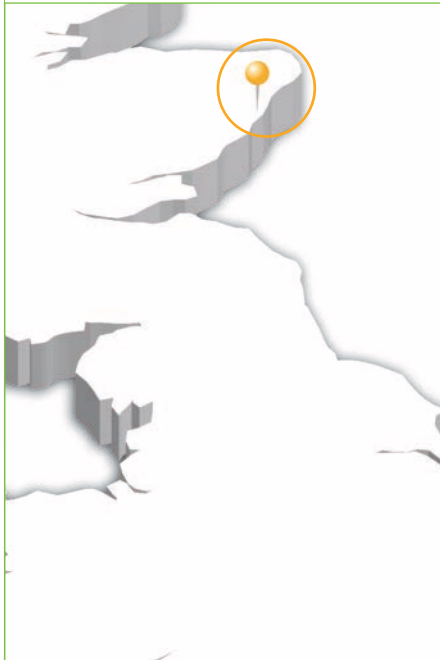

CONTENTS

- 05 **Radiography of the equine foot:**
Paul Smith, Westmorland Veterinary Group discusses radiography of the horse's foot.
- 06 **Managing pain in horses:**
Aimi Duff, Scott Mitchell Associates explains the management of pain in horses.
- 07 **Role of the equine veterinary nurse:**
Marie Rippingale, Scarsdale Veterinary Group looks at the role of the veterinary nurse within equine practice.
- 09 **Equine liver disease:**
Heather Urquhart, Scarsdale Veterinary Group discusses the causes, diagnosis and treatment of equine liver disease.
- 15 **Pre-purchase examination:**
Stuart Thorne, Fellowes Farm runs us through the pre-purchase examination.
- 17 **Anti-doping & controlled medication in competition:**
David Rowlands, Penbode Equine Vets explains the current anti-doping and controlled medication regulations.
- 18 **Vet viewpoint:**
We view the opinions of our vets on the topic of anti-doping and controlled medication in equine sport.
- 19 **Recent advances in the veterinary industry:**
XLEquine provides us with an insight into laparoscopy in horses.
- 20 **Equine keratoma:**
Lee Pritchard, Calweton Veterinary Group provides information on keratomas in horses.

SPRING FEATURES

- 03 **Equine foot balance:**
Graham Hunter, Ardene House Veterinary Practice explains what we mean by foot balance and its impact on performance.
- 11 **Angular limb deformities in foals:**
Toby Kemble, Wensum Valley Veterinary Surgeons discusses the assessment and treatment of angular limb deformities in foals.
- 13 **Case study:**
ALD Treatment with farriery and splinting, Sam Cutts, Hook Norton Veterinary Surgeons.
- 14 **Surgical feature:**
Management of angular limb deformities, Peter Bakonyi, Chapelfield Veterinary Partnership.



Veterinary surgeon **Graham Hunter**

XL Equine practice **Ardene House Vet Practice Ltd**



Graham Hunter BVM&S CertEP CertAVP(ESO) MRCVS,
Ardene House Vet Practice Ltd

Equine foot balance

What do we mean when we use the term foot balance?

It is a term used to describe the appearance of each foot and in particular, its size and shape. It also relates to how the foot dynamically functions and interacts with the ground i.e. how it lands and takes off again.

Conformation is often discussed in association with foot balance and is a slightly different concept. It relates to the shape and size of the individual parts of the limb and how they relate to each other. Ideally we want each foot to have a conformation that maximises its mechanical efficiency and if optimal, we could describe that foot as being balanced. In the adult horse, conformation cannot be manipulated or changed but balance can, so with appropriate trimming and shoeing, good balance can generally be achieved in most horses.

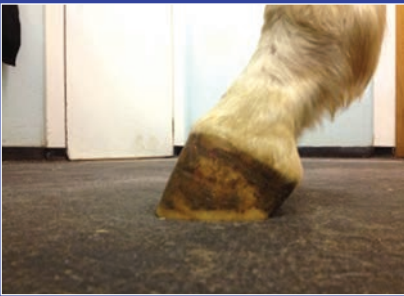As a result of repetitive stresses in the foot i.e. repeated contact with the ground, injuries

to the foot can occur and lameness will frequently result. Poor foot balance will contribute to these stresses and lameness is more likely to occur. By recognising poor foot balance and conformation problems early we can take action to reduce the risk of avoidable lameness in your horse.

It is important to consider foot balance as a three-dimensional concept. We describe the three dimensions separately using the mediolateral (side) view, dorsopalmar/plantar (front to back) view and the solar (sole of the foot) view. When discussing balance these views are normally described separately although it is important to understand that a change in one plane will influence and alter the others.

It is important to assess balance while the horse is standing still (static foot balance) as well as when the horse is in motion walking and trotting away and towards you (dynamic foot balance).





Static foot balance assessment showing a forward broken hoof pastern axis



Dynamic foot balance assessment with the right front foot landing very heavily on the outside of the foot



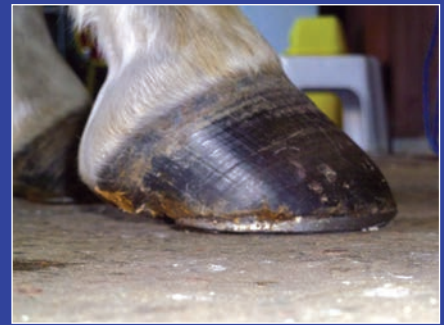Note the front wall, heel and pastern are all parallel

Static foot balance

Viewed from the side, the front of the hoof wall should be parallel with the pastern and the angle of the heel should again be parallel with the angle of the front wall.

Front feet and hind feet are slightly different in that the angle of the front wall to the ground surface is a little steeper in the hind feet. The forelimb front wall is often quoted as being about 55 degrees and in the hindlimb, is about 3 degrees steeper.

When the foot is viewed from the front, a line drawn down the centre of the cannon bone should come straight down the centre of the pastern and the centre of the foot so that each side is symmetrical. This line should also be perpendicular to the ground surface. A line drawn from the inside to the outside of the coronary band should be level and parallel with the ground surface.



Static foot balance assessment showing a backward broken hoof pastern axis with a poorly fitted shoe with very little support at the back of the foot

Looking at the bottom or the sole of the foot, the width and length of the hoof capsule should be approximately equal in the front feet. In the hind feet the length is invariably a little greater than the width.

Dynamic foot balance

This describes the placement of the foot as it contacts and then subsequently leaves the ground. We have always assumed that ideally, looking from the front, the inside and outside of the foot should contact the ground at the same time when

landing and when the foot leaves the ground the last point of contact should be the centre of the toe. From the side it is also assumed that the heel should land just slightly before the toe or they should land simultaneously.

What happens when the balance is wrong i.e. foot imbalance?

Many horses can tolerate a large degree of foot imbalance and will remain sound, while competing to a high level. Others are more sensitive, with a minimal discrepancy adversely affecting performance and resulting in lameness.

If the angle of the pastern is steeper than the foot, this is called a 'broken back hoof pastern axis'. This increases the load on the back of the foot during weight bearing and increases the stress at the toe when the foot breaks over as it leaves the ground. It also increases the tension on the deep digital flexor tendon and the forces on the navicular bone and puts stress on the coffin joint. All this will make the foot more prone to lamellar tearing, heel bruising, injury to the deep digital flexor tendon and navicular disease.

If the angle of the foot is steeper than the pastern, this is called a 'broken forward hoof pastern axis' (upright foot). This increases the load in the front half of the foot and reduces the tension in the deep digital flexor tendon. The main problems that arise from this are related to a predisposition to concussive injuries including subsolar bruising.

If mediolateral (side to side) imbalance is present this will cause asymmetry in the forces and stresses placed on the foot and can result in solar bruising, lamellar tearing, distortion of the hoof capsule, hoof wall cracks, sidebone, fractures, inflammation and possibly arthritis in the distal limb joints.

Correcting any imbalance can take four or five farrier sessions. In general, correction of the imbalance requires differential trimming of the hoof walls, with or without adjustments to the thickness of the branch of the shoe. If we have a mediolateral imbalance, the hoof wall on the high side should be removed with little or no trimming on the lower side. The amount of adjustment achieved will be limited by the amount of hoof wall that can be removed without making the horse lame.

If a horse has very poor foot conformation i.e. very toe in or very toe out, complete correction of the imbalance may be impossible. In such cases the vet/farrier team must strive to achieve the best possible balance for that individual, while accepting that achieving ideal balance may cause more harm than good.



Paul Smith BVM&S CertEP MRCVS, Westmorland Equine Vets

Radiography of the equine foot

The equine foot is one of, if not the, most common areas of interest for radiographic evaluation.

Foot pain is a major cause of equine lameness and radiography is an important diagnostic tool in identifying the location, extent and severity of any injury or disease within the foot. Its most important role is to give information about bones and joints, however, it can provide information about soft tissues such as tendons and ligaments, particularly where they attach to bone. Some common causes of foot pain which may be identified with the aid of radiography include pedal bone fractures, osteomyelitis (infection of the bone), osteoarthritis, laminitis and navicular disease (Figures 3 and 6).

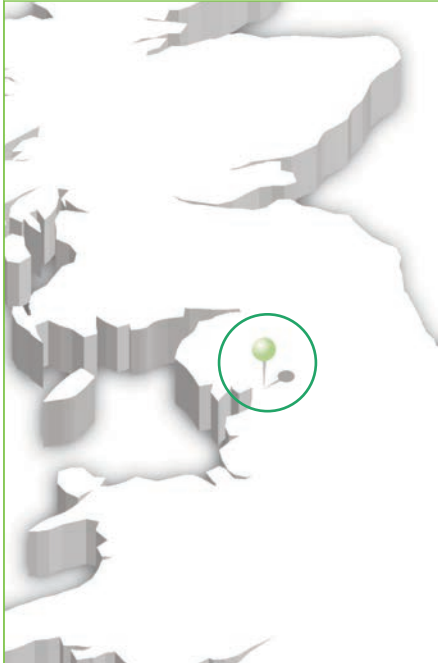
place can be useful when assessing foot balance and conformation as they allow accurate identification of the weight-bearing surface and the position of the shoe in relation to the hoof capsule and pedal bone. However, if a source of lameness has been localised to the foot, removal of the shoes may be required to obtain the additional views necessary to fully evaluate the foot.

In the absence of lameness, radiographic evaluation of the feet can also be used to provide information about foot balance and conformation. An animal which exhibits poor foot conformation, imbalance or abnormal patterns of growth will be at significantly greater risk of developing lameness as a result of abnormal forces on the bones and soft tissues leading to injury. Consequently radiography should be considered a powerful tool, not only in the diagnosis, but also in the prevention of lameness by providing information about the specific farriery requirements of an individual horse. Using radiographs, vet and farrier can work together as a team to maintain or improve a horse's soundness and performance.

Two views are usually required to fully assess balance of the feet, one lateral (taken from the side of the limb, see Figure 1) and one dorsopalmar (taken from the front, see Figure 2). Bone alignment, heel and toe length and sole depth can all be assessed on the lateral radiograph with particular attention being paid to the alignment of the pastern and pedal bones and their relationship to the hoof capsule, the so called 'hoof pastern axis'. A broken-back hoof pastern axis is a common abnormality, particularly in warmbloods, causing increased loading of the heels, straining the deep digital flexor tendon and supporting ligaments of the navicular bone (Figure 5). The dorsopalmar view is used to assess joint alignment, foot symmetry and the length of both the medial (inner) and lateral (outer) hoof walls (Figure 4). Excessive length on either side can affect the rest of the limb by causing uneven loading of joints, causing stress on collateral ligaments or leading to osteoarthritis.

The widespread use of mobile digital x-ray machines means that radiography of the feet is a straightforward procedure but it can take time to prepare and position the feet correctly so as to avoid the need, risk and expense of repeating images. Depending on the reasons for taking the radiographs, removal of shoes may or may not be necessary. For example, performing radiographs with the shoes in

Routine radiographic imaging of the foot can be an invaluable aid to trimming, shoeing, injury prevention, and treatment of injury, whether the goal is to simply keep the horse healthy and happy at pasture, or to facilitate optimal performance of a competitive equine athlete.



Veterinary surgeon **Paul Smith**
 XLEquine practice **Westmorland Veterinary Group**



- Fig. 1: Lateral view of the foot showing normal alignment of pastern and pedal bones
- Fig. 2: Dorsopalmar view of the foot showing normal symmetry of the foot
- Fig. 3: An unusual cause of foot pain. Barbed wire stuck in a coronary band wound
- Fig. 4: An example of poor mediolateral hoof balance
- Fig. 5: Poor hoof balance – a severely broken back hoof pastern axis
- Fig. 6: A case of laminitis showing rotation of the pedal bone in relation to the hoof capsule

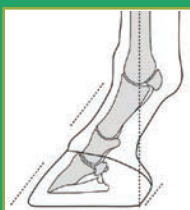


Fig. 1

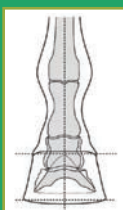


Fig. 2

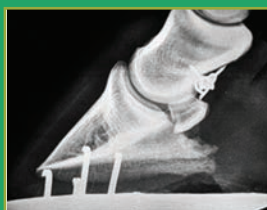


Fig. 3

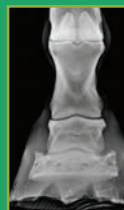


Fig. 4

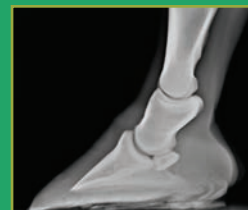

Fig. 5

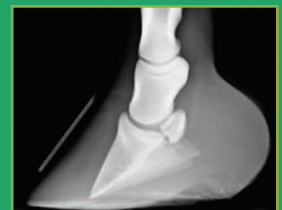
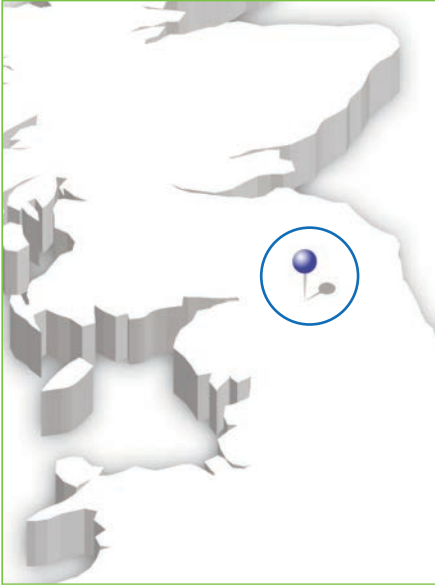


Fig. 6

Scott
& Mitchell
Associates
VETERINARY
SURGEONS



Veterinary surgeon Aimi Duff

XL Equine practice Scott Mitchell Associates



Aimi Duff BVM&S MRCVS, Scott Mitchell Associates

Managing pain in horses

Many diseases affecting horses cause pain. Uncontrolled pain can cause stress which in turn might adversely affect healing. The long term effects of chronic stress include weight loss, muscle loss, colic, aggression, stable vices (e.g. crib-biting, weaving), diarrhoea, immune suppression, inappetance, and gastric ulceration.

A key aspect of veterinary care is the provision of effective pain management and this can be achieved in several ways; pain relieving medications, provision of support and relieving pressure.

'Analgesia' is the term used to describe 'relief from pain' and an 'analgesic' is the drug used for this effect.

Chemical analgesia

There are several medications available for pain management in horses which have different mechanisms of action.

Non-steroidal anti-inflammatory drugs (NSAIDs)

NSAIDs are useful for reducing inflammation, fever and pain and are commonly used in equine practice for lameness and colic cases. Examples of NSAIDs used in horses include phenylbutazone 'bute', flunixin, and aspirin.

Treatment with NSAIDs can be short or long term, e.g. horses with degenerative conditions such as arthritis. When used long term it is recommended that the horse be checked every 6 months and a blood sample taken to check that the drug is not causing unwanted side-effects.

Side-effects associated with NSAID treatment in horses include:

- Gastrointestinal ulceration
- Oedema
- Diarrhoea
- Weight loss
- Kidney damage

The risk of side-effects is increased in foals, small ponies and dehydrated animals. In these cases concurrent drugs may be needed or hydration corrected to prevent complications.

a2-agonists

This class of drugs are commonly used to sedate horses but they do also have an analgesic effect. This can be particularly useful when pain is causing distress. This class of drugs are commonly used to sedate horses but they do also have an analgesic effect. This can be particularly useful when pain is causing distress.

Opioids

As with people, opioids like morphine can be used in horses to provide short term pain relief.

Opioids work on the central nervous system to reduce pain sensation in circumstances where NSAIDs are insufficient or contraindicated. They can be injected into muscle, direct into joints or as epidurals. Opioids can potentially cause excitability and constipation so their use must be carefully monitored and they are typically avoided in colic cases.

Opioids are most often used to provide pain relief for orthopaedic procedures during anaesthesia and in the post-operative period.

Ketamine

Ketamine is routinely used as an anaesthetic drug but also has analgesic effects.

Local anaesthetic drugs

Local anaesthetic drugs can be used to 'numb' nerves supplying a painful area such that the pain is no longer felt. By sequentially 'blocking' nerves that supply certain parts of the limb, vets can localise the painful region before x-raying or ultrasound scanning these areas; this is called 'diagnostic anaesthesia' or 'nerve-blocking'. Local anaesthetics might also be used to 'block' the area around a wound so that it might be stitched.

Physical methods of pain relief

Bandaging/splints

Simple or support bandages with splints can be used to provide support in cases of tendon/bone injury and this in itself can reduce the need for analgesics.

Relieving pressure

In cases of colic caused by intestinal obstruction the stomach and intestine leading up to the blockage can become full of fluid and food material. This causes the stomach and intestinal walls to stretch, in turn causing discomfort. By passing a long, soft plastic tube through the nose and into the stomach the vet can evacuate this material, making the colic patient more comfortable.

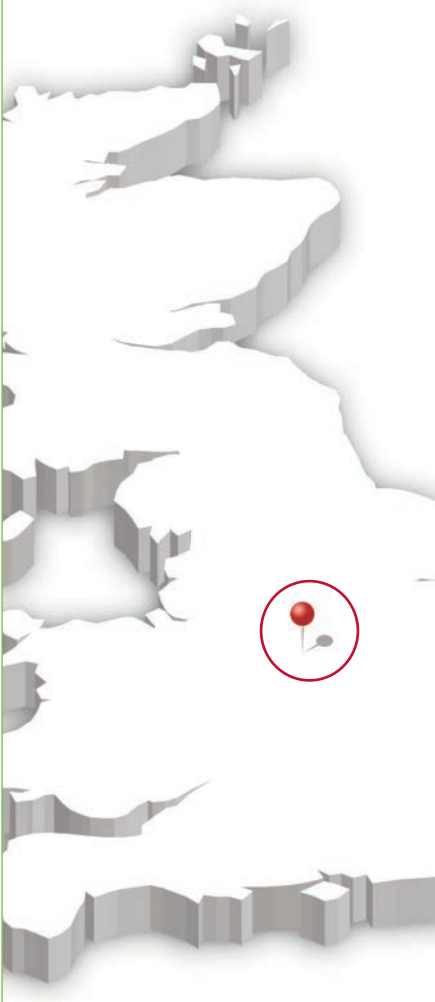
Another example where relieving pressure has an analgesic effect is where a horse is suffering from a foot abscess. The build up of pus within the hoof exerts pressure on the sensitive structures within the foot causing intense pain and lameness. By locating the pocket of pus and carefully paring to provide a drainage tract, the pressure is relieved improving comfort.



Marie Rippingale DipAVN (Equine) REVN,
Scarsdale Veterinary Group

Role of the equine veterinary nurse

Equine veterinary nursing is a dynamic and challenging vocation and in my opinion it is the best job in the world!



Veterinary nurse	Marie Rippingale
XLEquine practice	Scarsdale Veterinary Group

To be an Equine Veterinary Nurse (EVN) you have to have a strong love of horses but you also need to be disciplined, organised and capable of adapting to any situation. The first veterinary nursing training scheme was set up in 1961, but a specific equine veterinary nursing qualification was only introduced in 2000 and the first certificates awarded in 2001. Qualified EVN's carry out a number of functions in equine practice and are specifically trained in the following areas:

● Bandaging



● Caring for and supporting patients

● Assisting with the monitoring of anaesthetics

● Scrubbing in to assist with surgical operations

● Theatre practice

● Critical and emergency care

● Laboratory work

● Foot care

● Law, ethics and legislation

● Taking x-rays

● Giving medications



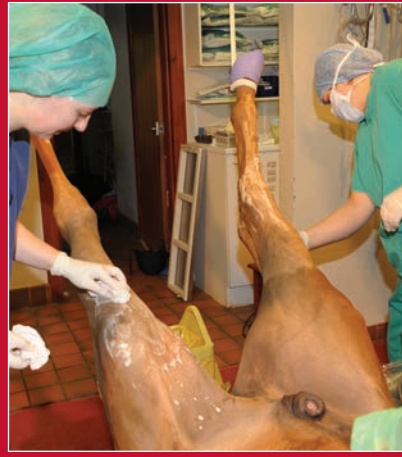● Administering fluid therapy



Role in the hospital

All procedures carried out by an EVN are under the direction of a veterinary surgeon in line with legislation, however, qualified EVN's are now eligible to apply to be on the RCVS Register to become a Registered Equine Veterinary Nurse (REVN). By registering, an REVN is demonstrating to employers and the general public that they are keeping their skills up-to-date accounting for their professional conduct. An REVN is required to complete an average of 45 hours of continuing professional development (CPD) over a three-year period and also follow the Guide to Professional Conduct for Veterinary Nurses. If things go wrong, an REVN would undergo a disciplinary process, similar to that for veterinary surgeons. REVN's work under the direction, but not direct supervision, of a veterinary surgeon. This means that as long as the treatment in question has been agreed by a veterinary surgeon, the REVN can proceed unsupervised in relation to tasks which they are qualified to carry out. In this respect REVN's are used extensively to free up veterinary surgeons in equine hospitals. REVN's can carry out procedures such as x-rays, intravenous catheterisation and bandage changes whilst the veterinary surgeon is free to go and perform other procedures. This makes the hospital/practice more efficient.

There is a large organising role to consider too, an REVN is often responsible for running the operating theatre and sometimes the pharmacy. The most important role the REVN has is monitoring and assessing the inpatients. The main goal is to ensure that patients recover as soon as possible. Veterinary nurses as a whole take a holistic view of patients which means the functioning of all body systems is taken into account as



well as those that are compromised. The patient's mental well-being will also be considered, as a happy patient will recover faster than a stressed patient. It is essential for an REVN to have a working knowledge of equine behaviour as this can be adapted to enhance care given. The REVN will provide plenty of necessary TLC for patients, using techniques such as grooming to mimic their natural behaviour encouraging them to relax and feel at ease. An REVN will monitor patients by regularly recording clinical parameters e.g. heart rate, temperature and respiratory rate. As well as recording parameters an REVN can identify abnormalities and instigate action to amend inconsistencies and improve patient welfare. This is where good communication skills are required, as an REVN must update the case veterinary surgeon regularly regarding the progress of their patients. As an REVN is mainly based at the practice they are always in close proximity to patients which makes monitoring more efficient. Producing patient care plans helps to guide holistic nursing of patients and encourages the use of evidence based medicine to improve standards of inpatient care.

Role in ambulatory practice



As well as working in the hospital, REVN's also have a role in ambulatory practice too. REVN's will often go out on visits with the vets to assist in taking x-rays. Ambulatory x-rays are usually required for laminitic patients or suspected fractures. It is not ideal to travel these patients to the hospital for investigation. Sometimes REVN's will also go out with the vet to assist with other procedures such as ultrasound scans, electrocardiograms (ECG's), endoscopy examinations and bandage changes. REVN's can also go out on their own to teach owners how to use inhalers for a condition known as Recurrent Airway Obstruction (RAO). This condition arises when the horse develops a hypersensitivity to dust and fungal spores in straw, shavings and hay. RAO causes breathing difficulties and an inhaler is often required to deliver medication straight to the lungs, where it is most effective. Being able to go out on visits is good for REVN's as they get a change of scenery and are exposed to first opinion cases that they wouldn't normally see in the hospital. It is also really nice to go out and meet new clients and patients and get to know new yards. From a client point of view it is good for them to meet the REVN's on the yard as then they will know who is looking after their horse if he/she ever gets admitted into the practice for treatment.

Role in education

REVN's are very much involved in client education through procedures such as admitting and discharging patients. Formulation of patient care plans also involves significant input from the client as details of their horse's normal behaviour and eating habits are required. Both the REVN and the client learn a lot during the formulation and use of the care plan, and this encourages the formation a nurse-client bond. This helps increase public awareness of the role of the veterinary nurse in practice. REVN's are also involved in client talks and courses at the practice,

as well as going out on visits. REVN's are used to help educate veterinary students that come to the practice as part of their degree course as well as teaching them how to perform TPR examinations, take x-rays, administer medication and perform bandage changes, and in doing so are responsible for educating the veterinary surgeons of the future. REVN's also train and teach the veterinary nursing students at the practice, guiding them through their three year course by providing practical and theoretical knowledge on a daily basis.

Conclusion

There is no normal working day for an REVN, you have to be versatile to work in practice, out on yards and to educate your colleagues, clients and veterinary students at all times. Emergencies can arrive at any time day or night and arranged procedures can change on an hourly basis. The way to survive is to adapt using professional judgement and skills to assist and support others in the veterinary team. Being an REVN is challenging, inspiring and heart breaking all at the same time however I still believe it is the most rewarding career you could ever choose.

Equine liver disease

The liver is one of the largest and most important organs of the equine body. It has many different functions, and as such plays a vital role in many important processes.



These functions include:

- Digestion of carbohydrates, fats and proteins.
- Detoxification of the blood before products absorbed from the gut can affect the rest of the body.
- Manufacturing of important products such as proteins, clotting factors and vitamins.
- Storage of vitamins, minerals and glucose.

Signs of disease

The multifunctional nature of the liver means that clinical signs are many, and vary widely between cases. Indeed, early signs may be subtle and easily overlooked, and signs of liver failure may not appear until more than 70% of the liver is damaged.

Specific clinical signs of mild-moderate cases of liver disease may include one or more of the following:

- Weight loss
- Lethargy
- Depression
- Decreased appetite
- Poor/reduced performance
- Poor coat quality
- Behavioural changes
- Abnormal faeces
- Jaundice
- Colic
- Photosensitisation (sunburn-like lesions on depigmented skin)

In more severe cases where the liver has already started to fail, signs such as excessive bleeding without clotting, fluid accumulation resulting in swelling of the legs and head, bilateral laryngeal paralysis causing severe respiratory distress, and central nervous system signs (these include head pressing, ataxia (incoordination/wobbliness), seizures, blindness, and coma) can be seen. In some cases, liver disease can be fatal.




Figure 1: Pony presenting with weight loss later diagnosed with liver disease

Veterinary surgeon **Heather Urquhart**
 XLEquine practice **Scarsdale Veterinary Group**



Diagnosis

As liver disease can manifest in different ways, diagnosis based on history and clinical signs alone is not normally possible, however certain combinations of signs may raise suspicion of liver involvement. The following diagnostic tests are commonly used both to diagnose liver disease and to help determine the cause, extent, severity and prognosis of the disease.

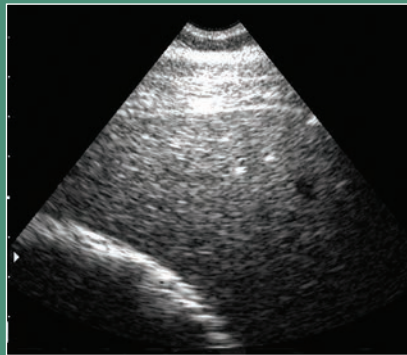
Blood work:

Damaged liver cells release enzymes into the bloodstream, which can be easily detected in a blood sample. However, some enzymes are also released by other organs in the body so careful interpretation is required, and although blood samples can indicate liver damage they do not give

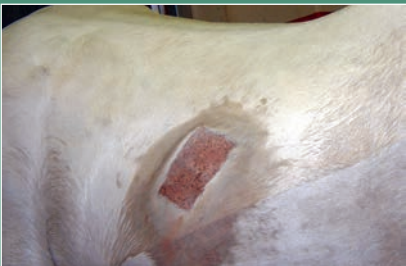any indication as to the cause. Bile acid levels can also be easily measured - increased bile acids indicate impaired liver function, and occur when the liver is already starting to fail. Infection and inflammation may also be detected, but again it is not possible to identify a cause.

Ultrasonography:

An ultrasound examination can give information about the size of the liver (for example smaller or larger than normal), as well as assess the liver tissue for bile duct obstructions, fibrosis or abscesses. In addition, it can be used as a guide for liver biopsy. This type of examination is straightforward, non-invasive and usually well tolerated. Your horse may require extensive clipping (especially if he is a hairier type!) on both sides of his chest, and may require light sedation to keep him still.



Liver biopsy site:



Liver biopsy is considered the 'gold standard' in the diagnosis of liver disease. A biopsy can provide information about the cause, best treatment options and prognosis of the disease.

The procedure involves inserting a special biopsy needle through the body wall and into the liver to obtain a thin strip of liver tissue. This process is then repeated until several samples have been obtained.

These tissue samples are then examined under a microscope to determine the type and extent of disease. If an infectious cause is suspected then a bacterial culture may also be performed.

The procedure is performed with the horse sedated and local anaesthetic injected into the skin and muscle layers overlying the biopsy site. Staples or sutures may be used to close the skin layer afterwards. In some cases a blood sample may be taken before the procedure to check that your horse's blood is clotting properly.

Causes of liver disease

Toxins, infections, inflammation, parasites, drugs (both naturally occurring and synthetic), starvation and neoplasia can all cause liver disease to varying degrees.

Plant toxicity is one of the most common causes of liver damage. Plants containing pyrrolizidine alkaloids, such as ragwort (*Senecio jacobea*), are particularly toxic and even small amounts can cause irreversible liver damage. Other toxins include mycotoxins and aflatoxins, which can be found in mouldy grains, and iron.

Liver infection most commonly occurs via the intestinal tract. Bacteria may form abscesses or infect the bile ducts and surrounding liver tissue. Inflammation can be primary, or can occur secondary to another cause of liver damage.

Many drugs are processed by the liver. Whilst these drugs may not cause direct liver damage, impaired liver function may affect their usefulness.

Fatty liver disease is a serious condition, usually affecting obese animals. It can occur when there is a sudden decrease in food intake or increased energy demand such as during pregnancy. The resulting negative energy balance results in fats being released from stores in the body, which accumulate in the liver and cause impaired liver function.

Treatment

Treatment depends on the cause, type and severity of the disease and is therefore often guided by liver biopsy results. In many cases, treatment with antibiotics, non-steroidal anti-inflammatory drugs or corticosteroids may be indicated, either alone or in combination.

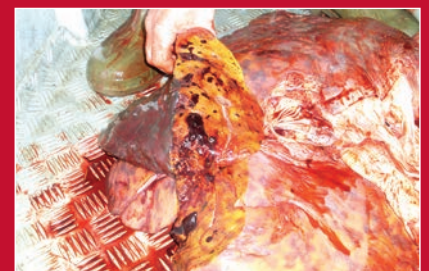
In cases where the signs of liver failure are already apparent, intravenous fluids and lactulose may be added to the treatment regime in order to try to flush the toxins out of the horse's system.

Vitamin supplementation is often necessary to prevent deficiencies developing.

In addition, milk thistle (*Silybum marianum*) has been shown to have a protective effect on the liver in humans, and is thought to be beneficial in horses.

Avoiding diets with high protein content is recommended, and in cases of fatty liver disease it is vital to provide high energy rations and encourage eating as soon as possible.

Liver damage:



Prevention

Although it may not be possible to prevent liver disease in all cases, avoiding over grazing of pasture and identifying and removing toxic plants as soon as possible will help.

In addition, regular blood samples in older horses or those on long term medication will help detect liver disease early when treatment may be more successful.



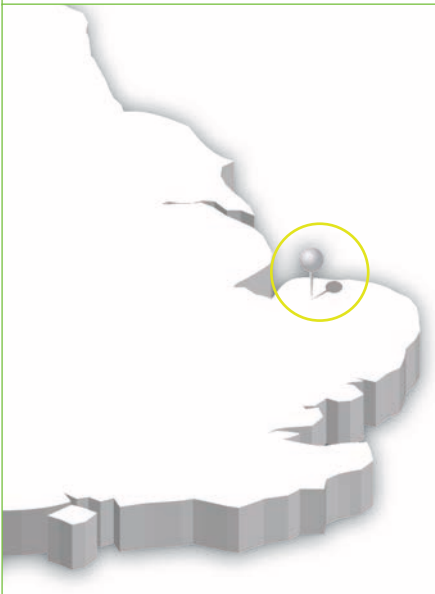Toby Kemble BVetMed MRCVS, Wensum Valley Veterinary Surgeons

Angular limb deformities in foals

Angular Limb Deformity (ALD) is the name given to a series of problems encountered in newborn and young foals.

It is a condition where the leg deviates either outwards (valgus) or inwards (varus) from the midline when viewed from the front or back. The joints most commonly affected are the knees, fetlocks and hocks. The

majority of ALD's are encountered at birth and are often associated with a problem during pregnancy. There are a number of different types of ALD's which have very different treatment regimes.



Veterinary surgeon	Toby Kemble
XLEquine practice	Wensum Valley Veterinary Surgeons



Category 1

Inadequate ossification

In the foetus, bones start off as cartilage and later calcium is deposited within; this process is known as ossification. One group of ALD's are caused by inadequate ossification of the small bones within the knee or hock. If the uterine environment is compromised in some way, e.g. infection, parasitism, nutritional problems, this ossification process can be interrupted resulting in the foal being born with weak, poorly developed bones. A similar problem is seen in premature foals whose skeleton has not had time to develop fully whilst in the uterus. When the foal stands, these complex joints can collapse resulting in deviation of the limbs.



A severe case of carpal valgus

Category 2

Growth plate problems

A second group of ALD's are the result of problems associated with the growth plates of the long bones of the limbs. These growth plates are at the ends of the long bones and are a region of dividing cells which ossify as they are produced. The faster they divide and ossify, the faster the increase in the length of the bone. If the growth plate is dividing quicker on one side than the other it will result in the limb deviating towards the side that is growing more slowly. Treatment is aimed at either slowing down the faster growing side or speeding up the slower growing side. The majority of these types of ALD's are seen at birth and it is not fully understood why they occur. Nutritional factors and positioning within the uterus are just two of many factors which have been implicated. ALD's can also occur in the growing foal as a result of damage to the growth plate, e.g. concussion injury from hard ground.

Category 3

Flaccidity of joint structures

A third group of ALD's can be seen either alone or in conjunction with either of the above two categories and they are as a result of flaccidity in the ligaments and other structures which hold the joints together. These are often seen in conjunction with flaccidity of the tendons, resulting in foals whose fetlocks are down on the ground. In most cases multiple joints will be affected.

Assessment of ALD's

The single most important decision when dealing with an ALD is to determine which of the previous categories it is that you are dealing with, bearing in mind it is common to see more than one category in the same foal or even joint. This is particularly the case in premature or dysmature foals (dysmature refers to foals which are not born early but show the signs of a premature foal). Radiographs (X-Rays) should be taken to assess the degree of ossification of the bones. This will help differentiate the first two categories. A radiograph taken from directly in front of the limb will show where the actual deviation is occurring, e.g. from within the joint or from the growth plate. If it is the former it is likely to be due to collapse of the joint, if the latter it is likely to be a growth plate problem.

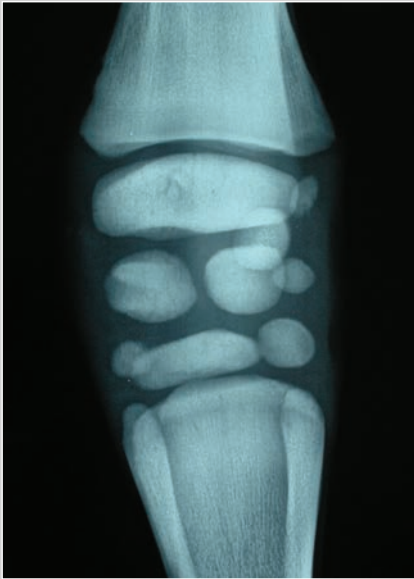


Figure 1: The carpal (knee) bones are poorly ossified and hence liable to compression damage.

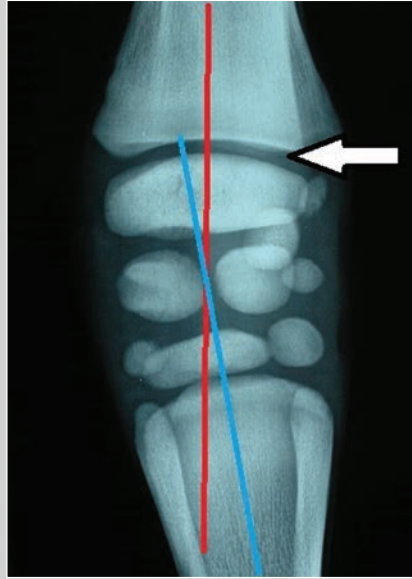


Figure 2: In comparison to figure 3, this image shows the intersection, and hence the cause, to be in the middle of the knee and is due to collapse of the poorly ossified carpal bones.

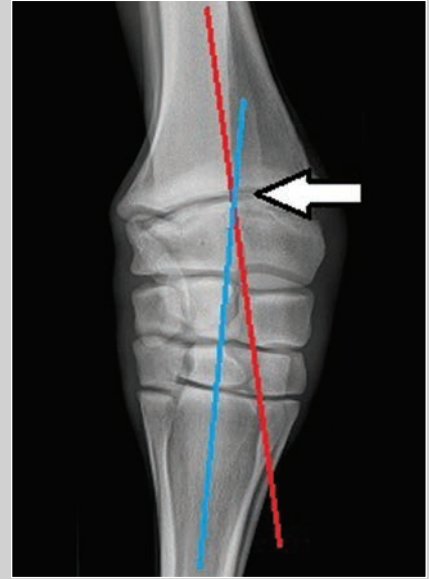


Figure 3: Ossification problem: The red lines indicate where the centre of the limb should run while the blue lines indicate where it actually is. The arrows indicate the growth plate; it is evident that the deviation is coming from the growth plate.

Treatment of angular limb deformity

Treatment options depend on the cause of the problem and its severity. In cases where there is mild flaccidity of the joint structures, good ossification of the bones and a deviation which can be temporarily manipulated back into line, box rest will often suffice. As the foal gains in strength the deviation will disappear. Cases caused by incomplete ossification may require support of the limb with the use of casts or braces. If these are not recognised at birth the joints may collapse and suffer irreparable damage. Growth plate problems are treated in a number of different ways depending on which joints are affected, their severity and at what age they are first noticed. Outward deviations of the knees (carpal valgus) are one of the commonest presentations we see, and in the majority of cases are self-correcting over the first couple of weeks of life. In contrast a turned-in fetlock (fetlock varus) is rarely

self-correcting and needs immediate attention because the growth plate responsible only produces new bone, and hence growth, in the first 3 months of life. If these are not treated quickly, treatment options become less effective. In contrast the distal radius growth plate which is involved with deviations of the knees will produce new bone for the first 6 months of life, giving a much longer treatment window, if necessary.




Summary...

ALD's are commonly seen in foals, particularly those that are premature or dysmature and must be assessed at the earliest opportunity to decide on the best course of treatment. At their mildest they will be self-correcting and will not affect the future athletic potential of the animal. At their most severe they can result in permanent disability and lameness.

Acknowledgements

Many thanks to Professor Tim Greet FRCVS of Rossdale Equine Hospital for the photographs.



Sam Cutts MA Vet MB MRCVS, Hook Norton Veterinary Group

Case study: ALD treatment with farriery and splinting

When this foal was born the owner immediately noticed an unusual sickle shape to his right hock. What had not been so immediately apparent to the owner was his bilateral hind-limb flexural deformities (contracted tendons) and marked right hind fetlock varus. It was suspected that he might have a problem with incomplete ossification (abnormal development) of the bones in his hock.

X-rays taken at 36 hours old fortunately did not confirm this, although there was still a concern that the tarsal (hock) bones might start to collapse if the current sickle shape could not be significantly improved. The x-rays demonstrated the very marked right fetlock varus (16.8°) and also a mild left fetlock varus (4.4°). Cost was a significant concern and it was decided to try conservative treatment in the first instance but to review the case at the 2 week stage and discuss whether surgery was required.

The foal was heavily sedated, given a mild pain-killer and placed on his side before a light dressing was placed on the left (more normal) hind-limb. A strip of padding bandage material was placed followed by multiple layers of pre-cut casting material moulded along the back of the leg before a top layer of padding bandage material was applied, thus forming a padding/cast sandwich along the back of the leg. The whole limb was bandaged with reasonable pressure using a cohesive bandage to encourage the half cast to form to the limb as it set. In order to reduce rubbing, the padding material was cut longer than the splinting material, and the ends of the splint were rolled away from the leg.

Whilst waiting for the splint to set the foal was treated with a high dose of intravenous oxytetracycline. This is an antibiotic which has long been known to have several useful side effects, and is particularly useful in the treatment of flexural deformities.

Once the splint had set on the 'good' leg it was removed and bandaged onto the 'bad' leg with reasonable pressure applied during application to encourage the leg to assume as normal a position as possible. Because the splint had been 'custom made' for the foal, minimal padding was required when compared with conventional gutter or wooden splints.

The foal was allowed to recover with assistance. The owner was directed to remove the splint daily to check for any rubbing and to apply gentle physiotherapy, by way of upward pressure on the foal's right hind toe. The splint was then reapplied and each day the limb was able to be pulled further into it. The mare and foal were kept on box rest. One week after birth the farrier attended to gently reduce the inside wall of the right hind foot and thus encourage the foal to stand straighter.

After two weeks a very pleasing improvement was seen. The varus angle was now less than 2 degrees! As the improvement was so great and the foal now no longer fit his original splint the decision was made to continue with corrective farriery only. The shape of the hock had improved slightly and there was no deterioration on subsequent x-rays. The contracted tendons had relaxed well. The foal progressed well and has now gone away to be backed.

Veterinary surgeon **Sam Cutts**

XLEquine practice **Hook Norton Veterinary Group**



Figure 1: Right hind fetlock varus




Figure 1

Figure 2: X-ray of the right hind fetlock

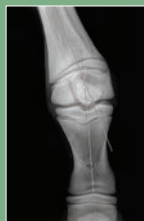

Figure 2

Figure 3: Setting up



Figure 3

Figure 4: Applying the first cast layer



Figure 4:

Figure 5: Waiting for the casting material to set (left leg)

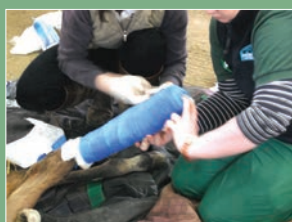

Figure 5

Figure 6: The splint in action (right leg)

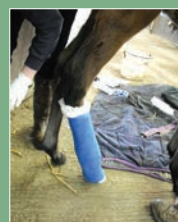

Figure 6

Figure 7: The foal 2 weeks later




Figure 7

Figure 8: X-rays at 2 weeks after initiation of treatment

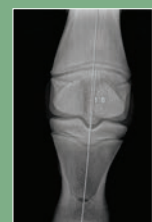
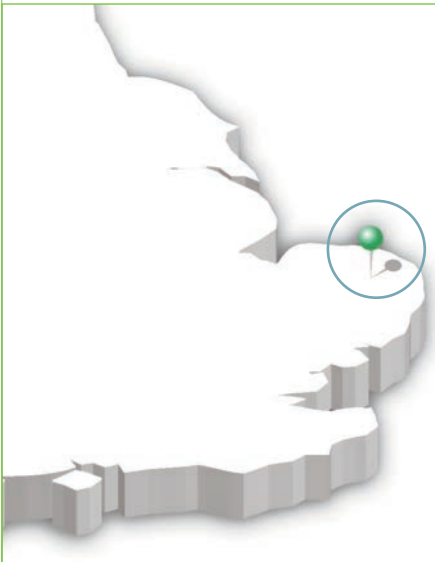

Figure 8



Veterinary surgeon Peter Bakonyi

XLEquine practice Chapelfield Veterinary Partnership Ltd

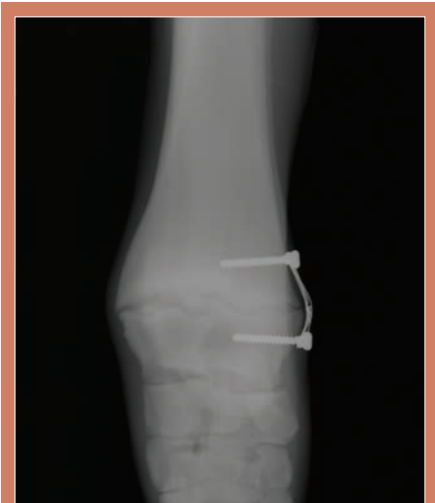

Figure 1: Intraoperative radiograph of the temporary transphyseal bridging technique with screws and cerclage wires in place. Valgus deformity of the knee.

Peter Bakonyi DrMedVet MRCVS, Chapelfield Veterinary Partnership Ltd

Surgical feature:

Management of angular limb deformities

Although most foals have less than ideal conformation at birth, the majority of angular limb deformities (ALD) resolve with conservative management. Some more severely affected foals or foals failing to respond to conservative treatment methods are candidates for surgical intervention.

Bone development

Growth plates are a highly specialised region at the end of long bones and have a crucial role in bone development. This narrow cartilaginous zone can adapt and respond to weight loading be it normal or uneven and it is responsible for longitudinal bone growth. However, at a well-defined time which is specific to each region it mineralises and hence growth stops. In general, the further down the limb the growth plate is located, the sooner it will become functionally inactive, making correction of ALD's of the fetlock and pastern more important early in life than those of the knee or hock.

Surgical treatment options

Surgical treatment of foals with ALD's is directed towards accelerating growth on the concave side (outside of an outward deviated limb) or slowing growth on the convex (inside of an outward deviated limb) side of the limb. The opposite is the case in deformities with inward deviation.

Periosteal transection - growth acceleration

This technique is performed on the concave aspect of the limb on the side where the growth plate is growing too slowly. Cutting the periosteum (fibrous membrane covering bones) releases tension across the growth plate allowing it to catch-up with the opposing side. It should be undertaken between four-six weeks old for the fetlock and before six months old for the knee.

Prognosis

Surgical correction of mild to moderate ALD's carries a good prognosis. However, it should be carried out in a timely fashion while the window of opportunity is still open.

Temporary transphyseal bridging – growth retardation

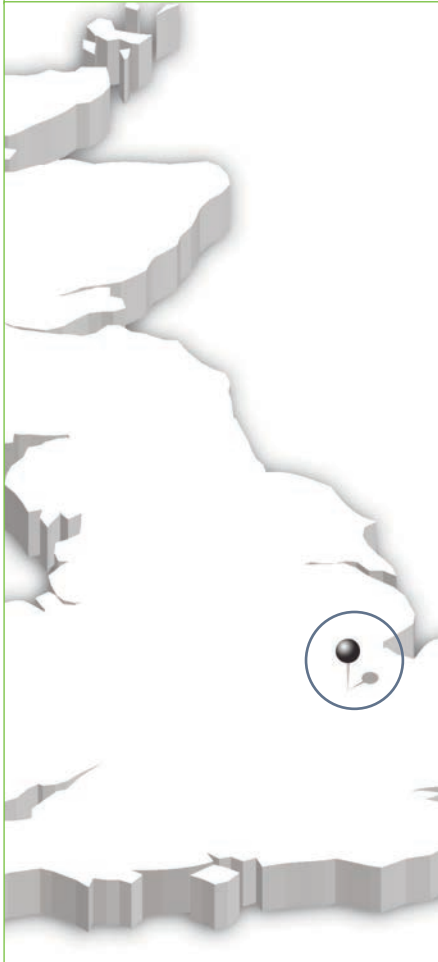This technique retards growth on the more active side of the growth plate. It is used in the fetlock from one-three months old, while on the knee or hock it may be performed at a later stage i.e. from around four and six months of age respectively.

The surgery involves placing a staple above or cortical screws on both sides of the growth plate under general anaesthesia. The screws are then connected with a wire (Fig. 1.). As the wire is tightened the pressure created retards the growth plate below allowing the opposite (less active) side to 'catch-up'. The implant is left in place until the required angulation of the limb is achieved. A second surgery is needed for implant removal.

The post-operative care for both techniques involves two-three weeks of box rest while the surgical site is covered with a bandage. During this period corrective hoof trimming should be performed.

Other surgical treatments

In older foals where growth plates become inactive or in the case of a crushed growth plate their surgical manipulation would be ineffective, corrective osteotomy has been adapted to horses from human orthopaedic surgery. This technically challenging procedure is less often performed.



Veterinary surgeon **Stuart Thorne**
XLEquine practice **Fellowes Farm Equine Clinic Ltd**



Stuart Thorne BVSc BSc PhD MRCVS
Fellowes Farm Equine Clinic Ltd

Pre-purchase examination

The aim of a 'vetting', or to use its more correct title, the Pre-Purchase Examination (PPE), is for a vet to carry out a thorough clinical examination on behalf of a potential purchaser to identify and assess factors of a veterinary nature that could prejudice a horse's suitability for its intended use.

Certificate and opinion

The certificate (Figure 1) reports the examination findings including all the significant signs of disease, injury or physical abnormality. Each PPE is performed on behalf of a specific purchaser so that the vet's final opinion can be based on that individual's needs and the intended use of the horse. This opinion is given in the following format. 'In my opinion, on the balance of probabilities, the conditions reported above do/do not prejudice this horse's suitability for purchase to be used for ...'

If, for example, the vet feels that their findings DO prejudice the horse's suitability as a 4* Eventer then they will delete the relevant section and the horse is often referred to as having 'failed'. However, the same horse could be examined by the same vet on the same day for a client who wants a quiet hack and the horse may 'pass' as the same findings DO NOT prejudice the horse's suitability for the intended use.

It is preferable to move away from the pass/fail mind-set. The PPE provides an assessment of the horse at the time of examination to help the potential purchaser make an informed decision as to whether or not to continue with their purchase. It is not a guarantee of a horse's suitability for the intended purpose but forms an important part of the risk assessment undertaken when someone is considering buying a horse. It is also often a requirement from an insurance company if the horse is over a certain value.

Before the examination can occur it should be established if the vendor is a client of the practice. It is standard procedure when a vet performs a PPE on a client's horse that the vendor agrees to allow full disclosure of previous clinical history held by the practice. If this is not possible, for any reason, then the vet should decline to perform the examination. It is important that there is no conflict of interest as the vet must act wholly in the interests of the purchaser.

Examination

The standard examination is conducted in five stages, although the exact sequence of the examination may vary. If requested by the purchaser, a limited (two-stage) examination may be performed. However, written confirmation is required from the purchaser confirming that they understand that the examination is limited in its scope as it may not detect important clinical factors that could otherwise influence the decision to purchase the horse (Figure 2).

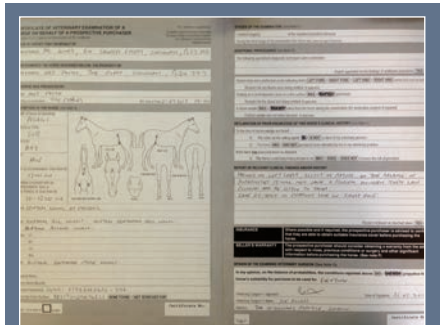


Figure 1

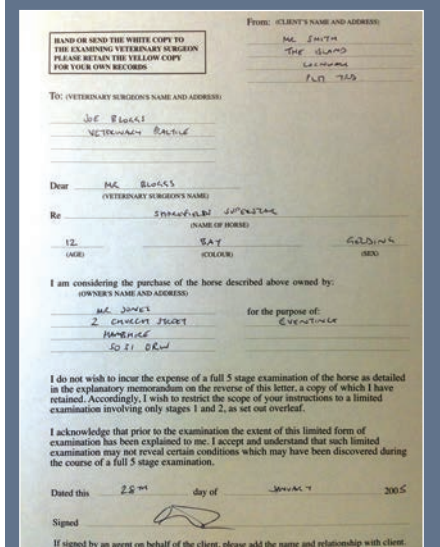


Figure 2

Stage 1: Preliminary examination

A thorough external examination of the animal at rest and includes an examination of the incisor teeth, examination of the horse's eyes in a darkened area and auscultation (listening) of the heart and lungs at rest (Figure 3). It does not include an examination of the inside of the prepuce (sheath), a detailed mouth examination with a speculum, a height measurement or any examination for pregnancy.

Stage 2: Walk and trot, in-hand

The horse is walked and then trotted in-hand to detect abnormalities of gait and action. The horse is turned sharply each way and is backed for a few paces.

Flexion tests of all four limbs (Figure 4) and trotting in a circle on a firm surface may also be carried out. These are not mandatory parts of the standard procedure and there may be circumstances when the vet concludes that it is unsafe, inappropriate, unsuitable or impossible to perform.

However, most purchasers expect them to be performed as they can provide useful

additional information and the certificate records whether or not they were done.

Stage 3: Exercise phase

The horse is usually ridden and given sufficient exercise to allow assessment when it has an increased breathing effort and an increased heart rate. Assessment of the horse's gait at walk, trot, canter and, if appropriate, gallop is also made. If ridden exercise is not possible then this stage may be conducted by exercising the horse on a lunge, but this fact should be made clear to the purchaser and on the certificate.

Stage 4: Period of rest and re-examination

The horse is allowed to stand quietly for a period during which time the respiratory and cardiovascular systems are monitored as they return to resting levels.

Stage 5: Second trot up

The animal is trotted in-hand again to look for any signs of strains or injuries made evident by the exercise and rest stages.



Figure 3



Figure 4

Blood sample

A blood sample can be taken for immediate testing or storage (usually for 6 months). This allows for detection of substances present in the horse's system at the time of the examination that might have masked factors affecting the horse's suitability for the purchaser's intended use. This helps protect both parties as the purchaser can buy in confidence and the

seller can if, for example, the horse becomes lame soon after purchase through no fault of their own or the purchaser can't cope with the horse, for whatever reason, prove that it wasn't 'doped' for the examination. If a blood sample is not taken then the reason for this is noted on the certificate.

Additional procedures

In some circumstances further specialised diagnostic techniques such as ultrasound scans, radiographs or endoscopic evaluation are undertaken. If the horse is going to be insured certain radiographs are often required. In general, the more expensive the horse the more radiographs the insurance company will require. It is important that the purchaser contacts their insurance company prior to the examination to clarify which radiographic views are required. The results of these additional procedures are reported and recorded on the certificate or in an addendum to it.

Identification of the horse

The diagram of the horse on the certificate may be omitted if the presence of a microchip can be confirmed by scanner and the diagram on an accompanying passport matches the horse. In this instance, both microchip and passport numbers should be recorded on the certificate.

Age

Without appropriate paper records from foal-hood it is not possible to confirm the age of a horse with accuracy. Estimates of age based on a dental examination are notoriously imprecise and unreliable.

Insurance

Where possible and if required, the prospective purchaser is advised to confirm that they are able to obtain suitable insurance cover before purchasing the horse.

Seller's warranty

A seller's warranty is a matter between the seller and the purchaser and is not the responsibility of the vet. The purchaser should consider obtaining a written warranty from the seller covering, for example, matters such as medical or surgical history, height, freedom from vices, temperament, non-administration of drugs prior to the examination and the horse's previous or existing uses and performance levels.



Veterinary surgeon **David Rowlands**

XLEquine practice **Penbode Equine**



David Rowlands BVSc CertEM(StudMed) MRCVS,
Penbode Equine

Anti-doping and controlled medication in competition

Do you know that horses can be dope tested at British Horseracing Authority (BHA), British Eventing (BE), British Dressage (BD), British Show-jumping (BS) and Fédération Equestre Internationale (FEI) competitions? Dope testing refers to diagnostic sampling used to detect prohibited substances that have the potential to enhance performance. Commonly used equine medications are on the FEI Prohibited Substance list. It's important that owners, riders, grooms and their home vets are familiar with the regulations and procedures. Rule violations will be penalised and could potentially result in a ban.

So why does the FEI dope test? The answer is simple; to maintain fair competition. It does this by enforcing regulations requiring horses to be free from certain performance enhancing substances; these are known as prohibited substances.

Prohibited substances are classified as either:

- **Banned substances** - have no legitimate use in the competition horse and/or have a high potential for abuse e.g. anabolic steroids or human anti-psychotic medication.
- **Controlled substances** - have therapeutic value and/or are commonly used in equine medicine. However, they may also affect performance, and/or be a welfare risk to the horse. E.g. non-steroidal anti-inflammatory drugs such as phenylbutazone 'bute'.

In most cases, those horses that are competing should follow the withdrawal times for the particular medication administered to the horse by your veterinary surgeon. There are however instances where in emergency situations the welfare of a horse close to competing may be at risk and treatment may need to be administered. In these cases, under FEI regulations a special form must be filled out and presented for retrospective authorisation and for determination, where appropriate, whether the horse can continue to compete at the event. There is no guarantee that these forms will be authorised.

A few general principles of good practice to reduce the chance of a positive dope test include:

- Use separate feed and water buckets for each horse in the yard. This should help reduce the chance of cross contamination.
- If a horse in the yard is receiving a controlled substance in its feed, prepare this last, wear disposable rubber gloves to prepare the feed, wash your hands and the buckets thoroughly afterwards.
- Communicate well with your vet. This is particularly important with regard to the dates of your upcoming competitions and whether these are governed by FEI, BHA, BE, BD or BS regulations.
- Only use feeds that are certified as free from prohibited substances and from reputable companies. Make a note of batch numbers whenever possible.
- Be cautious with supplements. Do not use 'home prepared' remedies.
- Never accept feed or supplements from other riders/grooms/teams.

Remember the FEI's philosophy is that horses must be clean at the time of competition. With this in mind, if in any doubt don't compete.

For the most up-to-date information, the FEI Equine anti-doping and controlled medication regulations can be downloaded from www.fei.org/fei/regulations/veterinary or for the BHA these can be downloaded from www.britishhorseracing.com.

VET VIEWPOINT...

WE ASK THE OPINIONS OF OUR VETS ON THE ANTI-DOPING REGULATIONS

Colin Mitchell BVM&S CertEP MRCVS
Scott Mitchell Associates



The majority of owners who compete their horses regularly will be aware of drug testing in their sport. These tests can take the form of the unexpected, random arrival of officials at a competition, to racing under rules where there will be at least one horse tested after the majority of races.

In recent times, testing by the British Horseracing Authority (BHA) found 14 positives in 7,000 tests.

In my opinion, and supported by the data above, the current regulations do appear to maintain fair competition. In my practice area, owners and trainers are accepting of the regulations and need for testing. I do not think anyone involved in the sport wishes to see a reduction in testing or an introduction of a no testing policy.

Fair competition benefits equine welfare, rider safety, public appreciation and integrity of the sport.



Are the anti-doping regulations in this country maintaining fair competition?

Laura Ruby BVSc MRCVS Calweton Veterinary Group



The use of substances with the potential to enhance equine performance, health or welfare and/or with a high potential for misuse are contrary to the integrity of

equestrian sport and the welfare of the horses. It is therefore essential that anti-doping programmes and protocols are implemented and enforced.

Anti-doping regulations are essential to maintain fair competition; officials can take samples randomly during events as well as regular testing of horses after competition. However, although the British Horseracing Authority and Fédération Équestre Internationale regularly 'dope test' this does not always filter down to the lower levels of affiliated competition.

So my answer would be yes, the anti-doping regulations do maintain fair competition but perhaps only at the top levels of competition.

Edward Chinn CertEP BVetMed MRCVS
Alnorthumbria Veterinary Group




The British Horseracing Authority has a zero tolerance to doping. Horses must be free from the effects of any prohibited substance. The definition of a prohibited substance is 'a substance which originates externally to a horse', therefore any medicine or supplement. To enforce this they will collect urine and blood samples at racecourses as well

as performing unannounced visits to training yards to sample all horses on the yard.

How effective is this? In 2012 there were 14 positive tests from a total of 7,182 post-race samples (0.19% of horses sampled) there were 90,174 runners that year (0.01% of all runners).

The Fédération Equestre Internationale (FEI) controls most other equine disciplines, they have lists of prohibited substances and of permissible medicines if declared. The FEI have vets at events sampling winning horses as well as randomly selected horses. These tests are incredibly sensitive, they can detect tiny amounts of naturally occurring banned substances inadvertently included in feeds or supplements.

I do believe the regulations maintain fair competition.



Recent advances in equine surgery

Minimally invasive surgery - laparoscopy

One of the most significant advances in the field of surgery is the introduction of minimally invasive surgical techniques. Although laparoscopy in horses was first reported in the 1970's it has undergone much transformation in the past 40 years and has not until recently become the standard of care for the surgical treatment of a number of conditions. Although there are applications within thoracic, abdominal and joint surgery we shall focus solely on abdominal surgery and specifically laparoscopy.

Laparoscopy (also known as 'keyhole surgery') is a type of surgical procedure that allows a surgeon to access the inside of the abdomen without having to make large incisions within the skin. Laparoscopy is a minimally invasive procedure that has applications as a diagnostic, prognostic and therapeutic technique.

The procedure involves placement of a long rigid camera called a laparoscope through a small incision to view inside the body. The image from the camera is viewed on a large monitor. Further small incisions are made and cannulae (tubular portals) are placed in these incisions to allow passage of long-handled surgical instruments to assist in the surgery.

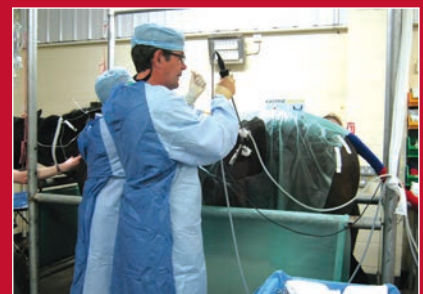In some cases, instruments may not be able to completely perform the surgery. In these instances, in combination with laparoscopy, a larger incision is made that the surgeon

can put their hand through. This is called hand-assisted laparoscopy.

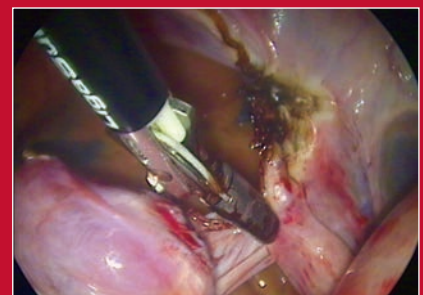Laparoscopy is a skilled and technically challenging surgical procedure as it relies on triangulation. Triangulation occurs when two or more instruments are placed through the body wall and move towards the area of interest. When instruments are too close to each other or too far away from one another it makes surgical manipulation difficult. The procedure relies on a skilled and experienced surgeon.

Not only is it important to have an experienced surgeon but investment in specialised equipment is required to perform laparoscopic surgery; a 57cm laparoscope, digital camera, light source and carbon dioxide gas insufflator are required as well as an array of laparoscopic specific operating instruments.

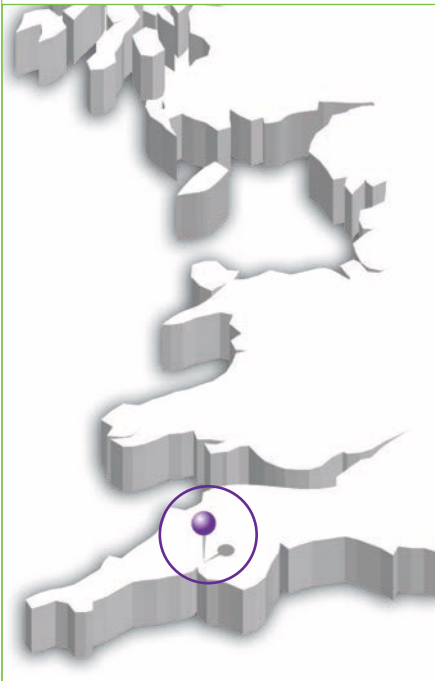Common laparoscopic procedures performed on horses include ovariectomy (surgical removal of the ovaries), cryptorchidectomy (removal of a retained testicle), adhesiolysis (removal of bands of scar tissue that form between organs), repair of rectal tears, bladder stone removal, nephrectomy (removal of a kidney) and herniorrhaphy (hernia repair). Laparoscopy can be performed standing, under sedation and local anaesthetic, or under general anaesthetic in horses; the decision is made based on surgeon preference, patient status or the procedure being performed.



Laparoscopy allows access to the abdomen through small incisions and can be performed on the standing patient

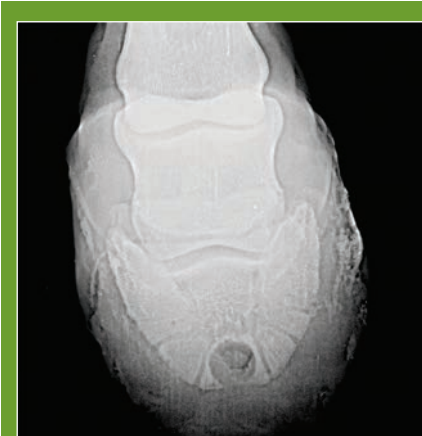


Laparoscopic ovariectomy



Veterinary Surgeon **Lee Pritchard**

XLEquine Practice **Calwetton Equine**



Spherical keratoma at the toe

Lee Pritchard BVSc MRCVS, Calwetton Equine

Equine keratoma

A keratoma is an uncommon, benign tumour originating from horn-producing cells in the foot, typically starting under the coronary band and growing down with the normal hoof. As they continue to grow, separation between the hoof wall and sole can occur allowing bacteria to penetrate the foot. The result of which is abscess development.

The exact cause of keratoma formation is unknown, but some veterinary surgeons believe that trauma to the hoof or chronic irritation of the sensitive laminae is linked to their development. Injury or inflammation of the coronary band has also been suggested as a possible cause. Two types of keratoma are recognised; these are spherical and cylindrical referring to their shape.

Initial presentation is most often foot abscessation; recurrence of the abscess at the same site is suspicious. Diagnosis of a keratoma is made by x-ray examination of the foot. In some complicated cases, magnetic resonance imaging may be necessary for diagnosis. The resulting pressure from the keratoma on the pedal bone typically results in the appearance of an indentation in the pedal bone due to loss of calcium in the bone. Once the diagnosis has been made, treatment for keratoma is via surgical removal. This can be done under standing sedation and local anaesthesia or general anaesthesia.

Surgical removal is performed by either complete or partial wall resection and this depends on the position, size and extent of the keratoma. The procedure involves the use of an electrical burr to make an incision through the hoof wall to gain access to the keratoma for removal. In those patients undergoing the procedure standing this is performed sedated with nerve blocks to remove sensation and a tourniquet to reduce bleeding. Once the hoof wall has been removed overlying the keratoma, the tumour can be carefully removed. Stabilisation of the hoof capsule is important as the wall will become unstable if sufficient amounts have been removed; often a bar shoe, thermoplastic pad and crack plate are placed by a farrier to achieve this.

Post-operative care is a prolonged process on-going over several months as the deficit in the hoof wall initially needs to granulate but long term needs to grow out. In the immediate post-operative period, dressings are changed regularly to control bleeding and to prevent development of infection. Administration of anti-inflammatories is important to control discomfort and in some cases the administration of antibiotics may be necessary to control infection.

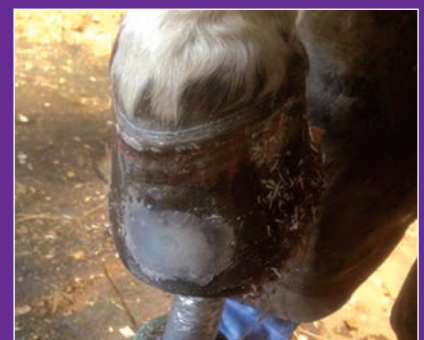
Assuming minimal post-operative complications and proper healing, the deficit in the hoof

wall can be filled with a glue or resin such as a methacrylate or polyurethane. This cannot be performed until sufficient healing has occurred as when setting they produce marked amounts of heat which can cause problems when placed on sensitive parts of the foot. In most cases, at six weeks onwards post-operatively these can be applied.

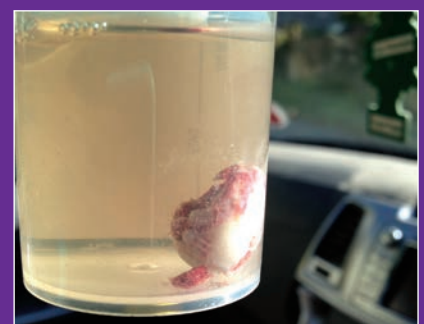
Methods of preventing keratoma formation are currently unknown mainly because they aren't fully understood. If your horse sustains an injury to their coronary band this should be investigated immediately and treated promptly.



One week post op



Filled hoof wall defect at six weeks



Spherical keratoma after removal



pony pages

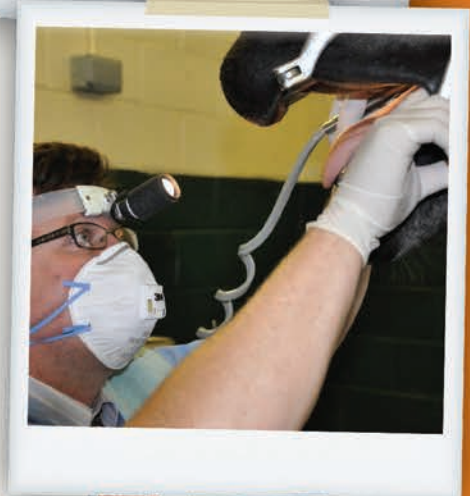Welcome...
TO THE SPRING 2015
XLEQUINE PONY PAGE



Top Tips

Managing your pony's weight from Jane White BVetMed MRCVS, St Boniface Veterinary Clinic

- ✓ Nature intended ponies to lose some weight during the winter months so don't allow them to start the spring in too fat a condition.
- ✓ Get your pony's teeth checked so they can chew food properly and without pain.
- ✓ Use a weigh tape and learn to 'fat score' your pony - do this fortnightly.
- ✓ Most ponies will get enough (often too many) calories from grass alone so they do not need extra hard feed if in light work.
- ✓ Weigh out any hay or hard feed and check if it is appropriate with either your XLEquine vet or a feed specialist.
- ✓ Feed according to work done and make any changes in diet gradually.
- ✓ Steady regular exercise will assist with weight control.
- ✓ Is that rug necessary? If your pony is always kept warm and dry then excess calories are not burnt off but laid down as fat.
- ✓ Control grass intake. If your pony is overweight or a 'good doer' then try either strip grazing the paddock or fence off a U shaped area so they move about more. Consider grazing with other ponies or sheep. Grazing muzzles work well for some ponies.
- ✓ If overweight aim for a steady weight loss, avoid crash diets and starvation paddocks. Fibre is still needed little and often to promote a healthy gut.
- ✓ Consider soaking hay for 12 hours to reduce its sugar content. However a vitamin/mineral supplement may then be required.
- ✓ Always ensure access to clean water.





Would you like to grow your equine knowledge?

Spanning the length and breadth of the UK, the XLequine member practices work together to share experience, ideas and skills in order to define and deliver the highest standards of equine care.

We are committed to providing you with the most up-to-date training through our practical and hands-on EquineSkills workshops, enabling you to provide the best care for your horse or pony. Our workshops are delivered to small groups of horse owners by our experienced veterinary team, providing a consistently high level of training across a range of topics and catering for all levels and abilities from experienced riders to the absolute beginner, meaning that you gain knowledge and skills that can be used straight away back on the yard.



Visit our stand
at this year's Your Horse
Total Confidence Live Event,
West Sussex on the
25th & 26th April 2015

**Exclusive sponsors
of the Vet Zone!**

Please note dates are
subject to change



Upcoming EquineSkills Courses

	4 March	Oxfordshire
	Equine Foot Care	
	4 March	East Sussex
	Equine Foot Care	
	24 March	Derbyshire
	Equine Foot Care	
	14 April	Northumberland
	Horse And Rider First Aid Training	
	14 April	Herefordshire
	First Aid For Your Horse	
	14 April	Devon
	Understanding Your Horse's Back	
	18 April	Cumbria
	Equine First Aid	
	21 April	Derbyshire
	How Do Horses Learn?	
	13 May	Cheshire
	First Aid For Your Horse	
	14 May	East Sussex
	Horse And Rider First Aid Training	
	19 May	Northumberland
	Equine Foot Care	
	9 June	Cumbria
	Equine Foot Care	
	9 June	Northumberland
	Equine Foot Care	
	16 June	Herefordshire
	Equine Foot Care	
	22 June	Derbyshire
	Understanding Your Horse's Back	
	29 June	Norfolk
	Understanding Your Horse's Back	
	30 June	East Sussex
	Understanding Your Horse's Back	
	27 July	Northumberland
	Understanding Your Horse's Back	

Book online today at
www.equineskills.co.uk

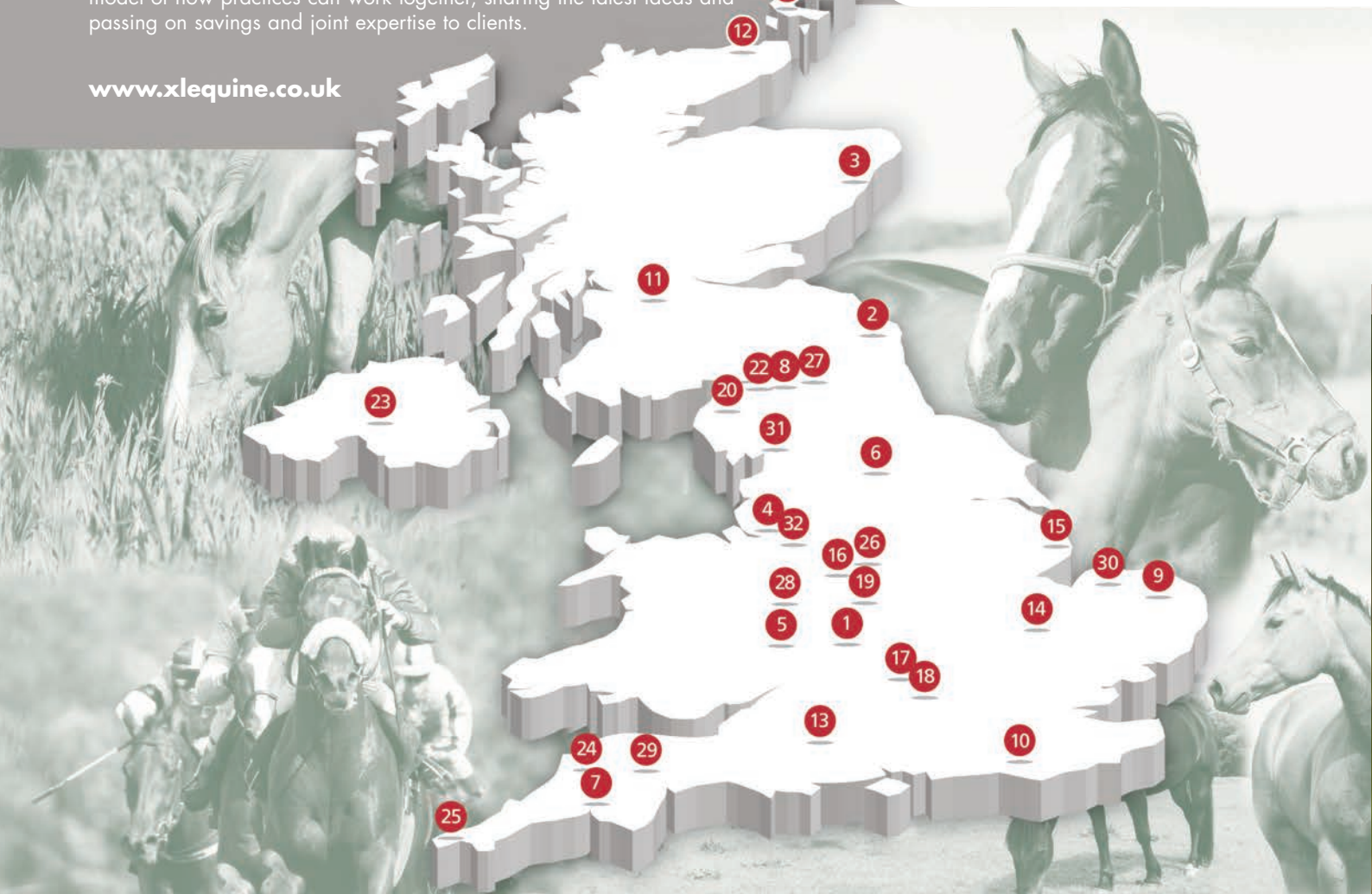
or contact us on 01765 608489/training@xlvets.co.uk

EXCELLENCE IN PRACTICE

XLequine - Better Together

The members of XLVets have worked hard to create what they see as a model of how practices can work together, sharing the latest ideas and passing on savings and joint expertise to clients.

www.xlequine.co.uk



1	608 Farm and Equine Veterinary Surgeons Rowington, Warwickshire Telephone: 01564 783404	9	Chapelfield Veterinary Partnership Norwich, Norfolk Telephone: 01508 558228	17	Hook Norton Veterinary Group Banbury, Oxfordshire Telephone: 01608 730085	25	Rosevean Veterinary Practice Penzance, Cornwall Telephone: 01736 362215
2	Alnorthumbria Veterinary Group Morpeth, Northumberland Telephone: 01670 897597	10	Cliffe Veterinary Group Lewes, East Sussex Telephone: 01323 815120	18	Larkmead Veterinary Group Wallingford, Oxfordshire Telephone: 01491 651479	26	Scarsdale Veterinary Group Derby, Derbyshire Telephone: 01332 294929
3	Ardene House Vet Practice Ltd Aberdeen, Grampian Telephone: 01224 740700	11	Clyde Veterinary Group Lanark, Lanarkshire Telephone: 01555 660000	19	Midshire Veterinary Group Limited Nuneaton, Warwickshire Telephone: 02476 384064	27	Scott Mitchell Associates Hexham, Northumberland Telephone: 01434 608999
4	Ashbrook Equine Hospital Nr Knutsford, Cheshire Telephone: 01565 723030	12	Donald S McGregor & Partners Thurso, Caithness Telephone: 01847 892387	20	Millcroft Veterinary Group Cockermouth, Cumbria Telephone: 01900 826666	28	Severn Edge Veterinary Group Aston Munslow, Shropshire Telephone: 01584 841080
5	Belmont Veterinary Centre Hereford, Herefordshire Telephone: 01432 370155	13	Endell Veterinary Group Salisbury, Wiltshire Telephone: 01722 710046	21	Northvet Veterinary Group Kirkwall, Orkney Telephone: 01856 873403	29	St Boniface Veterinary Clinic Crediton, Exeter Telephone: 01363 772860
6	Bishopton Veterinary Group Ripon, North Yorkshire Telephone: 01765 602396	14	Fellows Farm Equine Clinic Huntingdon, Cambridgeshire Telephone: 01487 773333	22	Paragon Veterinary Group Carlisle, Cumbria Telephone: 01228 710208	30	Wensum Valley Veterinary Surgeons Fakenham, Norfolk Telephone: 01328 864444
7	Calweton Veterinary Group Callington, Cornwall Telephone: 01579 383231	15	Fenwold Veterinary Practice Spilsby, Lincolnshire Telephone: 01790 752227	23	Parklands Veterinary Group Cookstown, Northern Ireland Telephone: 028 867 65765	31	Westmorland Veterinary Group Kendal, Cumbria Telephone: 01539 722692
8	Capontree Veterinary Centre Brampton, Cumbria Telephone: 016977 2318	16	Glenthorne Veterinary Group Uttoxeter, Staffordshire Telephone: 01889 562164	24	Penbode Equine Vets Holsworthy & Okehampton, Devon Telephone: 01409 255549	32	Wright & Morten Macclesfield, Cheshire Telephone: 08458 330034